

**PROCEEDINGS OF THE
NORTH AMERICAN VETERINARY CONFERENCE
VOLUME 20**

**JANUARY 7-11, 2006
ORLANDO, FLORIDA**



SMALL ANIMAL EDITION

Reprinted in the IVIS website (<http://www.ivis.org>) with the permission of the NAVC.
For more information on future NAVC events, visit the NAVC website at www.tnavc.org

LATERAL EAR CANAL RESECTION AND ABLATION IN PET RABBITS

Vittorio Capello, DVM
 Clinica Veterinaria S.Siro
 Clinica Veterinaria Gran Sasso
 Milano, Italy

ANATOMY OF THE RABBIT EAR

Similar to dogs, the ear canal of rabbits contains a vertical portion and a shorter horizontal tract. In the natural free ranging species of Lagomorphs, the two portions are separated just by a slight curve. In the dwarf lop breed, which has the aesthetic peculiarity of the long, hanging ear pinna (similar to hound breeds of dogs), the two portions are separated by the flexion of the cartilage at the base of the ear. This also causes a flexion of the ear canal, absent in the original species, *Oryctolagus cuniculus*, and is the result of man-made selection.

The anatomical difference is well appreciated during endoscopy of the normal ear canal in a dwarf non-lop vs. a dwarf lop rabbit. In the first breed the ear canal appears wide, conical shaped and allows clear

visualization of the tympanic membrane, while the ear canal in lop rabbits is smaller and visualization more difficult.

The anatomy of the rabbit ear, with blood vessels and nerves, is demonstrated in Figure 1.

OTITIS EXTERNA AND DIAGNOSTICS

Otitis externa is infrequent in dwarf rabbits, but common in dwarf lop breeds, as anatomic features predisposes them to bacterial otitis externa and media. Otitis externa may be related to parasitic diseases (*Psoroptes cuniculi*), traumatic injuries (hematoma of the ear pinna) or bacterial disease.

In cases of otitis externa, waxy debris may be particularly abundant in the vertical ear canal and can be appreciated with a rigid otoscope. Hyperplastic folds of the skin and a stenotic ear canal are also visible.

Radiographs of the tympanic bullae are another important diagnostic tool, and should be performed with the patient placed in ventrodorsal or dorsoventral position under general anesthesia. Lesions of the bullae strongly suggest the presence of otitis media.

Cytology, and culture and sensitivity of material from the ear are also useful as a support to medical therapy.

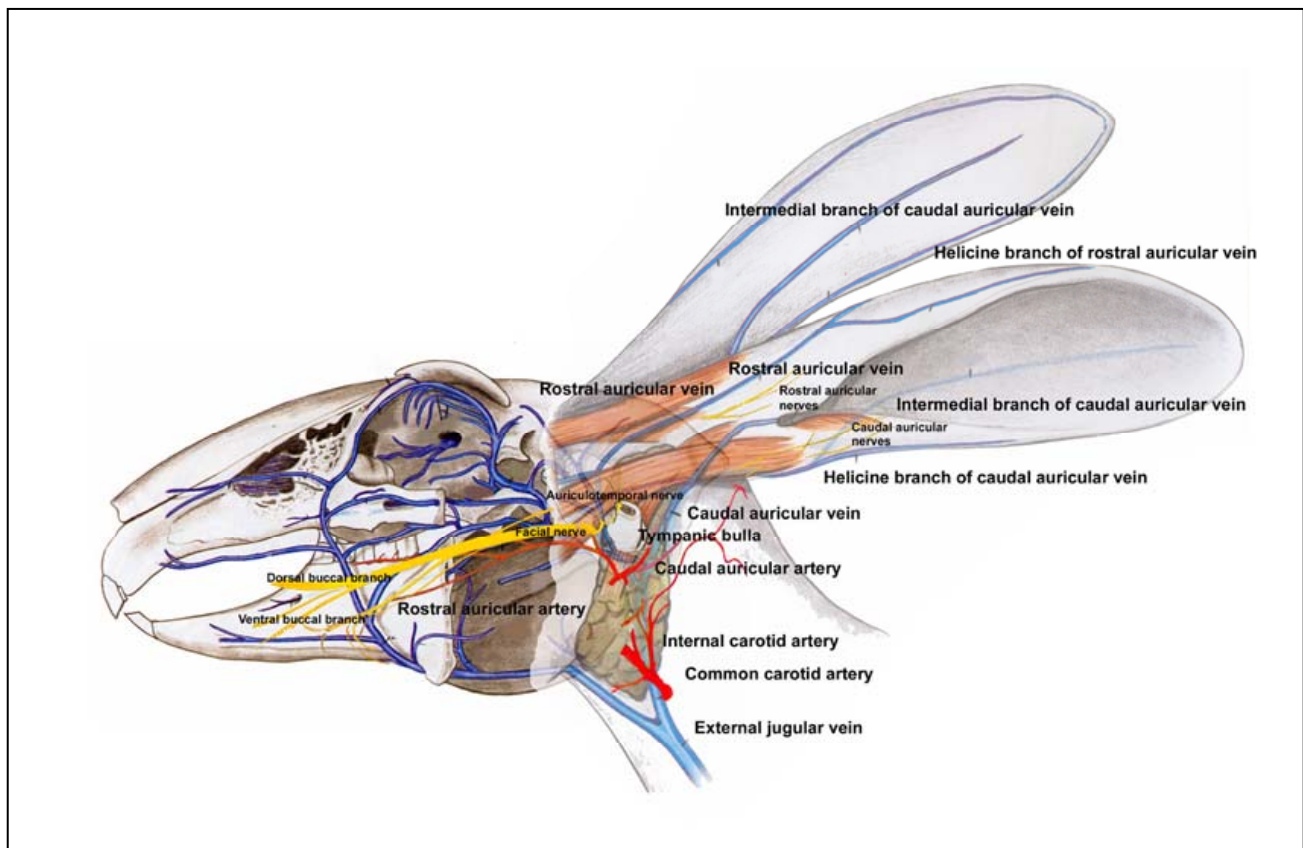


Figure 1. Vascular anatomy of the rabbit ear. Modified from Popesko: "A color atlas of anatomy of laboratory animals."

LATERAL EAR CANAL RESECTION

Due to the difficulty of cleaning and flushing of the ear canal, both in conscious and anesthetized patients, lateral ear canal resection with permanent otostomy is a good surgical option to resolve otitis externa and to prevent development to otitis media.

The rabbit is placed in lateral recumbency under general anesthesia, shaved around the base of the ear and aseptically prepared. The surgical drape, ideally transparent and adhesive, is applied and properly cut to expose the skin. Two parallel skin incisions are made at the base of the ear following the direction of the pinna. The skin strip created by the two skin incisions and associated subcutaneous tissue is dissected free from the surrounding cartilage, and reflected rostrally.

The lateral wall of the vertical ear canal is dissected through two parallel incisions performed with scissors. The cartilage is dissected ventrally to the level of the horizontal tract of the ear canal. Accurate dissection of soft tissues prevents injuries to the rostral and caudal auricular veins.

The rectangular cartilaginous strip is reflected rostrally, transected at the base and removed, revealing the opening of the horizontal tract of the ear canal. Significant hemorrhage does not usually occur, and bleeding can be controlled with electrosurgery, radiosurgery or direct pressure.

The round cartilaginous edge of the opening of the horizontal tract is carefully sutured to the surrounding subcutaneous and cutaneous tissues using a 5-0 absorbable suture in a simple interrupted pattern, then the remaining horizontal tract of the ear canal is flushed to remove purulent debris. The edge of the ventral portion of the vertical ear canal is sutured to the skin with absorbable 4-0 suture material in a simple interrupted pattern (Figure 2). Routine antibiotic and analgesic therapy is administered postoperatively.

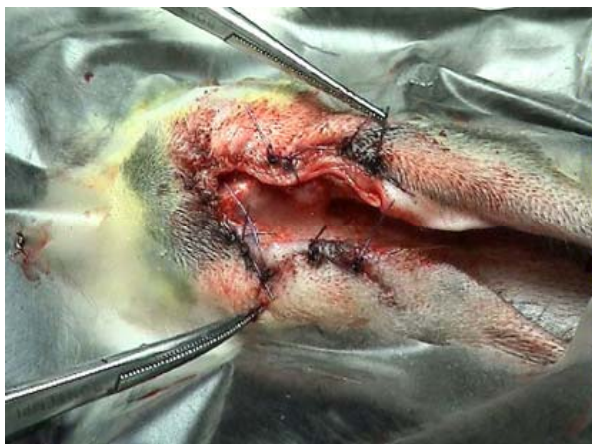

Figure 2.

After lateral otostomy, the ventral portion remains open and the horizontal tract opens laterally reducing collection of debris and allowing cleaning and flushing. During the first week of postoperative care, small crusts

are present over the sutures. They can be gently removed after flushing with saline. Sutures are removed about 10-12 days after surgery, together with the crusts. About 16-18 days post surgery, the surgical wounds are completely healed.

OTITIS MEDIA AND DIAGNOSTICS

Otitis externa can progress to involve the middle ear. In severe cases of otitis externa, a large amount of thick purulent material is visible up to the level of the ventral ear canal. Usually, cleaning and flushing the ear canal are ineffective treatments at this stage.

Otitis media is very painful. The affected rabbit may show anorexia, depression, pain on palpation at the base of the ear cartilage. Keratoconjunctivitis sicca might also be present. Medical therapy with antibiotic and analgesics is often unrewarding.

Otitis media can also result in central vestibular syndrome, with head tilt and nystagmus. Other pathologies causing vestibulitis must be ruled out.

During endoscopic examination the ear canal is usually filled by white and thick pus, and the tympanic membrane cannot be visualized. Radiographic lesions involving the tympanic bullae are visible as irregular radiodensities.

TOTAL EAR CANAL ABLATION AND OSTECTOMY OF THE TYMPANIC BULLA

Purulent otitis media must be surgically addressed like any other abscess affecting rabbits, with opening, thorough debridement, and postoperative flushing. For those reasons, total ear canal ablation and ostectomy of the tympanic bulla is the treatment of choice for this deep-seated infection.

The anesthetized rabbit is placed in lateral recumbency; and the area around the base of the ear is shaved and aseptically prepared. The skin is incised at the base of the ear, and the lateral wall of the ear canal is dissected from subcutaneous tissue. The dilated ear canal appears after dissection. The ear canal is dissected from surrounding tissues without actually entering the canal. Care must be taken to avoid accidental rupture of the canal (Figure 3).

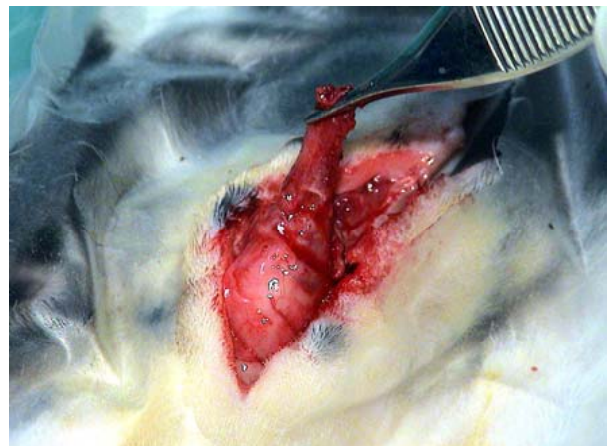


Figure 3.

The vertical tract of the ear canal is completely dissected from the pinna. Dissection close to the cartilage prevents injuries to the rostral and caudal auricular veins.

The horizontal tract of the ear canal is gently dissected free from surrounding tissue to the level of its junction with the tympanic bulla, and total ablation of the ear canal is performed. Purulent material can be seen exiting the tympanic bulla.

The ostium of the tympanic bulla is widened, carefully using a rongeur or a burr, to allow the flushing and the debridement of the bulla. Osteotomy is important to prevent recurrence of abscessation. The subcutaneous tissue surrounding the vertical ear canal is closed with absorbable 3-0 suture. Soft tissues around the opened tympanic bulla are marsupialized, creating a new, distal opening for postoperative flushing (Figure 4).

References

1. Bojrab MJ, Constantinescu GM, Treatment of otitis externa. In: Current techniques in small animal surgery, 4th ed. William & Wilkins, 1998; 98-101.
2. Capello V, Surgical treatment of otitis externa and media in pet rabbits. Exotic DVM 2004; 6.3:15-21.
3. Harcourt-Brown F, Otitis externa. In: Textbook of rabbit medicine. Oxford, UK, Butterworth-Heinemann, reprint of Elsevier 2002; 232-233.
4. Murray MJ, Application of rigid endoscopy in small exotic mammals. Exotic DVM 2000; 2.3:13-18.
5. Popesko P, Rajtovà V, Horák J, A colour atlas of anatomy of small laboratory animals. London, Wolfe publishing Ltd, 1992; 26,27,33.
6. Smeak DD, Total ear canal ablation and lateral bulla osteotomy. In: Current techniques in small animal surgery, 4th ed. William & Wilkins, 1998; 102-109.

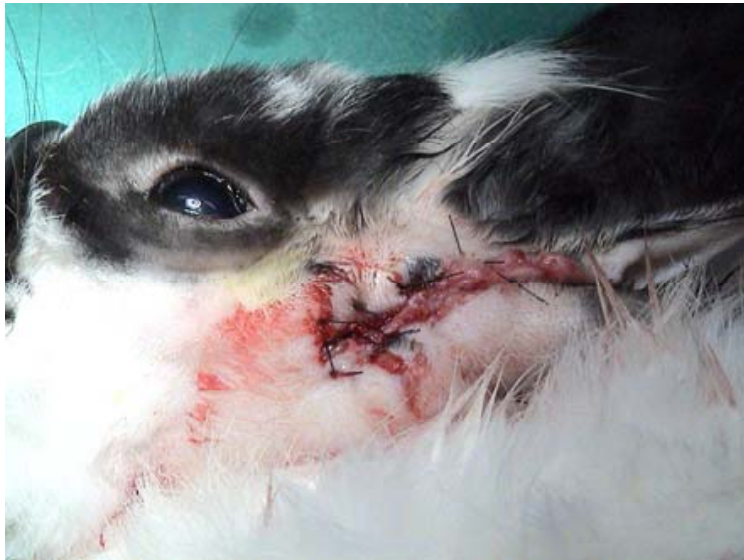

Figure 4.