

A group of wild rabbits, likely cottontails, are shown in a grassy field. The rabbits are of various shades of brown and grey, with long, upright ears. They are positioned in the foreground and middle ground, looking in different directions. The background is a soft-focus green field.

Viruses of the wild and domestic rabbit
(*Oryctolagus cuniculus*)

Esther van Praag, Ph.D.

2020

DOI: 10.13140/RG.2.2.34425.21609



DNA viruses: Adenovirus
Herpesvirus
Parvovirus
Papilloma virus
Poxvirus

RNA viruses: Astrovirus
Borna virus
Calicivirus
Coronavirus
Rotavirus

References

Thanks



DNA viruses: Adenovirus

Herpesvirus

Leporid herpesvirus

Human herpesvirus

Parvovirus

Papilloma virus

Shope papilloma virus

Oral papilloma

Anal papilloma virus

Rabbit kidney vacuolating virus

Poxvirus

Myxoma virus

Shope fibroma virus

Rabbit poxvirus



Adenovirus

Adenovirus

- First isolated from rabbits in Hungary and Québec ;
- Affects young weaning rabbits, older animals have developed immunity;
- Low mortality (10-15%);
- The virus causes enteritis with profuse diarrhea and dehydration in young rabbits;
- Found in kidneys, lungs and intestines ;
- It binds to rabbit red blood cells;
- Study revealed that rabbits have antibodies against bovine adenovirus type I;
- *Escherichia coli* has been found in the small intestine and the cecum, so it is speculated that this bacterium is associated to the disease.



Herpes virus

- A Herpes virus infection affects the skin, the respiratory tract, genital organs or causes fatal encephalitis.
- It can remain subclinical, without disease, and become active during after a stressful period or a disease.
- Two types of herpes affecting rabbits:
 - *Herpesvirus sylvilagus* or Hinze Herpesvirus Lymphoma
 - *Herpesvirus cuniculi* or rabbit virus III
- Once infected, a rabbit will have the virus throughout its life.

372

Jin, Valentine, Baker, Löhr, Gerlach, Bildfell, and Moerdyk-Schauwecker

Vet Pathol 45:3, 2008

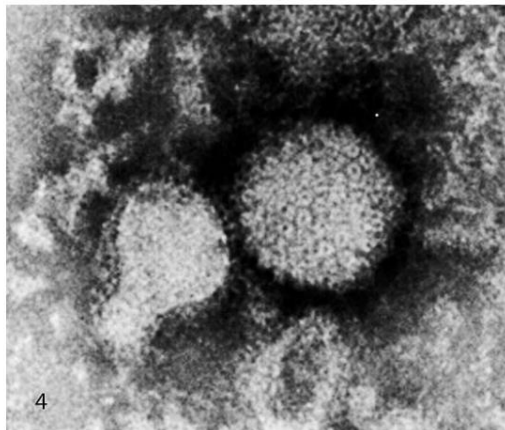


Fig. 4. Viral particles harvested from infected RK-13B cells. The virus exhibits symmetrical icosahedral morphology with a core diameter of approximately 100 nm and a surrounding capsule. Transmission electron micrograph, negative staining with 1.5% phosphotungstic acid.



Rabbit specific Herpes virus

Herpes sylvilagus

Affects Lagomorph species;

Transmission through feces, urine, copulation, through the air or during lactation;

Signs

- It mainly affects the tonsils in the throat;
- Lymphocytosis and leukocytosis;
- Lymphoid tissue injuries, as well as the kidneys, liver, lungs and heart;
- Splenomegaly;
- Benign and malignant transformation of tumors is possible.

Diagnosis

The virus is present in the oral cavity, in lymphocytes or in the kidneys.

Herpes cuniculi

Affects wild European rabbits;

Male rabbits that have survived a *Herpes cuniculi* infection become carriers of the virus and spread throughout the colony.

Signs

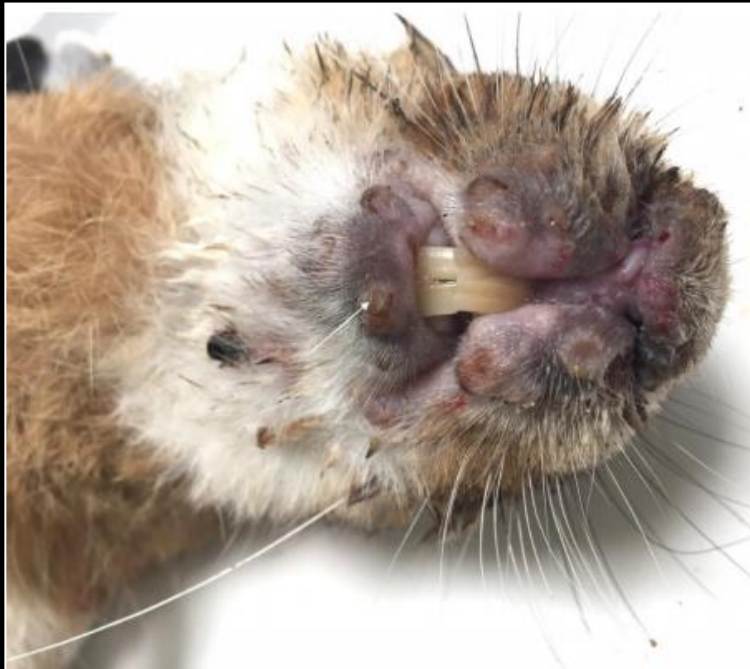- Fever;
- Rash on the skin that look like blisters;
- Damage to the cornea.



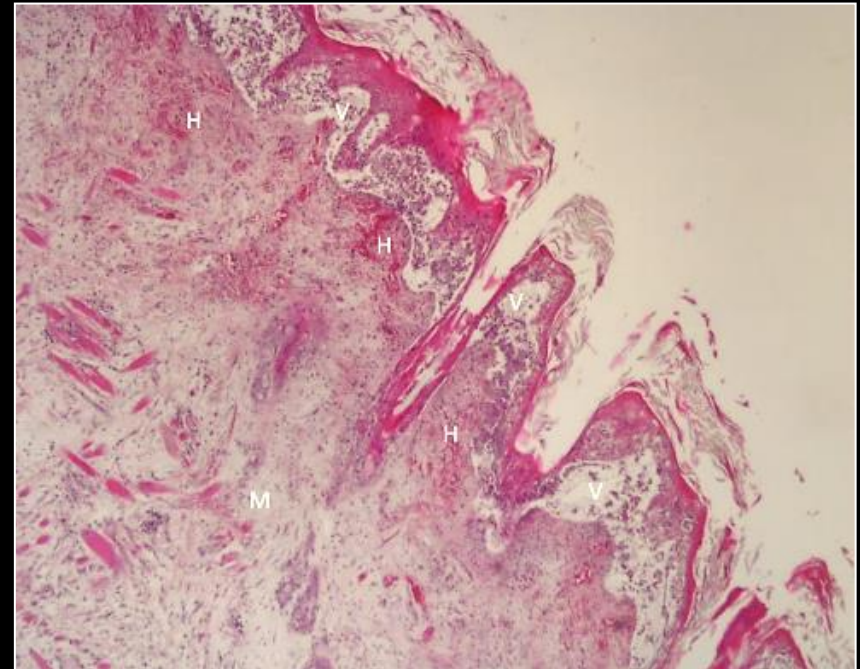
First description of a herpesvirus infection in genus *Lepus*

Abade dos Santos, F.A.^{1,2*}, Monteiro, M.¹, Pinto, A.³, Carvalho, C.L.¹, Peleteiro M.C.², Carvalho, P.¹, Mendonça, P.¹, Carvalho, T.³, Duarte, M.D.^{1,2}

Running title : First Herpesvirus in Iberian hare.



Lower lip vesicle of hare #25456/19 (arrow).
Nodular thickening of lips and eyelids.



Histopathological examination of the lip of hare #25456/19. M-mixomatous tissue in the dermis, microhemorrhages, V-Intraepidermal vesicopustules between the dermis and the epidermis. H&E, 40x.



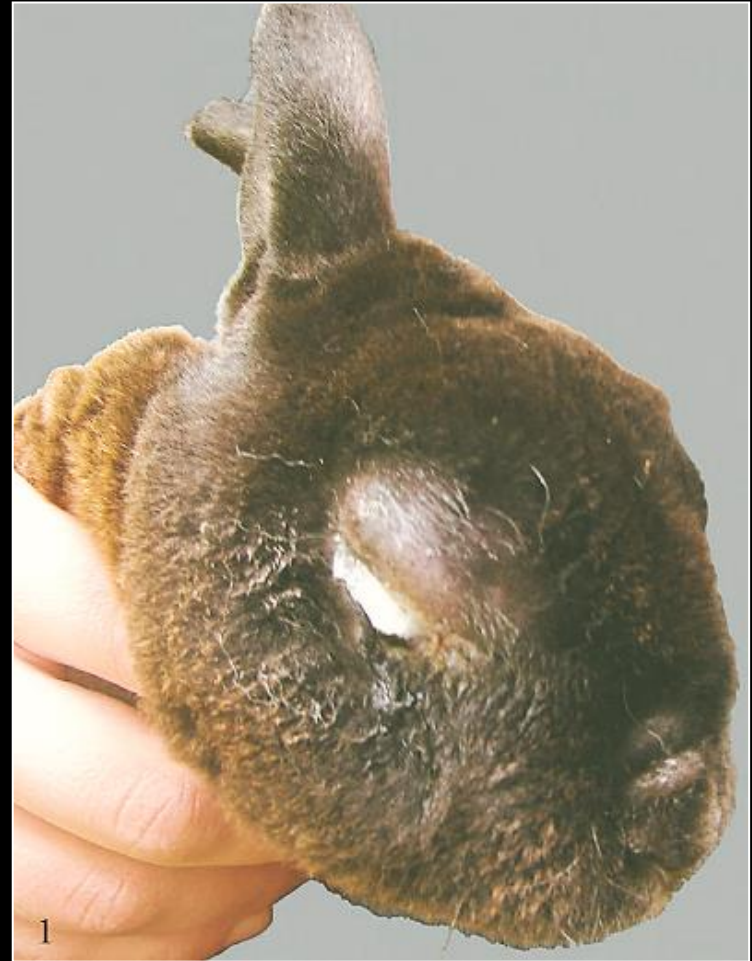Pet rabbit Herpes virus

Likely a new **alphaherpesvirus**

This virus has been isolated in Alaska, in a 6-week old Rex rabbit.

Signs

- Slight swelling and ulceration of the anogenital skin;
- multiple 0.3- to 1.0-cm-diameter nodular thickenings within the skin of the back, ventral abdomen, and pelvic limbs;
- severe hemorrhage within the subcutis on section;
- swelling and subcutaneous edema of the muzzle;
- Mucoid red tinged nasal discharge;
- Enlarged peripheral lymph nodes with hemorrhage on section.



Naturally highly pathogenic Herpes virus in mini Rex



Other Herpes viruses affecting rabbits

Herpes simplex

The *Herpes simplex* virus can be transmitted from man to rabbits. It has cause fatal meningitis in these animals.

Signs

- Acute conjunctivitis;
- Hemorrhagic dermatitis;
- Pneumonia;
- Necrotizing enlargement and inflammation of the spleen (splenitis).

Case Report

Journal of Veterinary Diagnostic Investigation
2014, Vol. 28(2) 189-191
© 2014 The Author(s)
Reprints and permission:
sagepub.com/journalsPermissions.nav
DOI: 10.1177/1042726613514111
jvdi.sagepub.com

Spontaneous fatal *Human herpesvirus 1* encephalitis in two domestic rabbits (*Oryctolagus cuniculus*)

Ricardo de Matos,¹ Duncan Russell, William Van Abstine, Andrew Miller

J. Comp. Path. 2002, Vol. 126, 308-311
doi:10.1053/jcpa.2002.0546, available online at <http://www.idealibrary.com> on IDEAL®

SHORT PAPER

Herpes Simplex Encephalitis in a Domestic Rabbit (*Oryctolagus cuniculus*)

P. Grest, P. Albicker*, L. Hoelzle*, P. Wild† and A. Pospischil

*Institute of Veterinary Pathology, *Institute of Veterinary Bacteriology, and †Institute of Veterinary Anatomy, University of Zürich, 8057 Zürich, Switzerland*

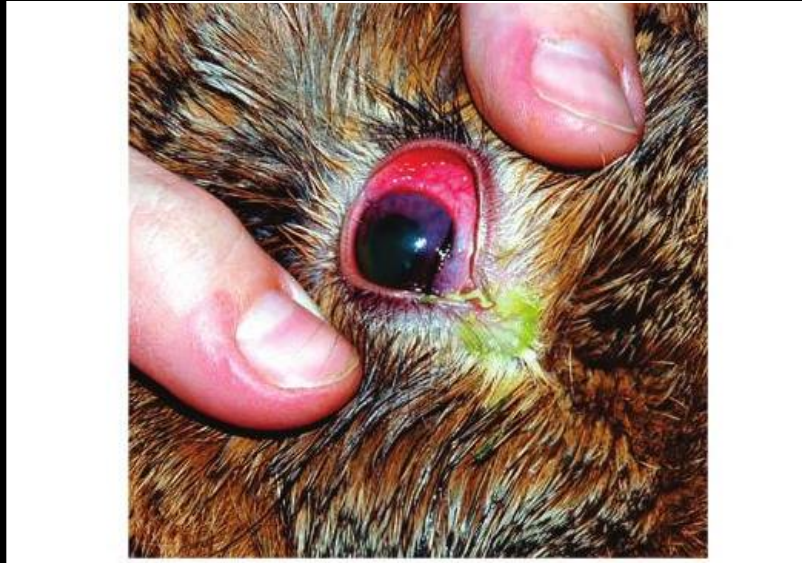

FIG. 6.8. Acute conjunctivitis in a rabbit naturally infected with herpes simplex virus infection following transmission from an infected human. (Source: Muller et al. 2009. Reproduced with permission from the American Veterinary Medical Association.)



Shope papilloma virus



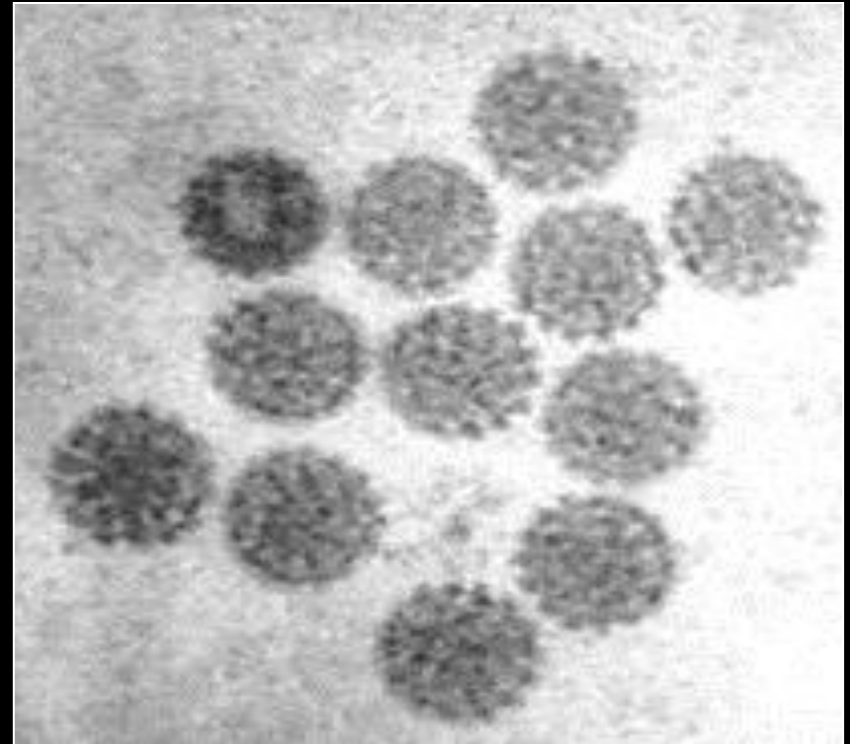
in hares and cottontails



Shope papilloma virus

Shope papilloma virus

- Known as the "cottontail rabbit" papillomavirus, this is the natural host.
- Characterized by the presence of keratinized warts in the neck, shoulders, ears or abdomen, (never in the mouth).
- Natural disease in wild and domestic rabbits.
- Transmitted via arthropod vectors like fleas, mosquitoes.
- Papilloma's were obtained when experimentally when *Nippostrongylus muris* larva infected with the virus were applied to the rabbit's skin.





Shope papilloma virus

Signs:

Horned warts, mostly on the neck, shoulders and abdomen.

Benign papilloma's can turn into malignant tumors. 25% of papillomas become malignant and develop into squamous carcinomas.

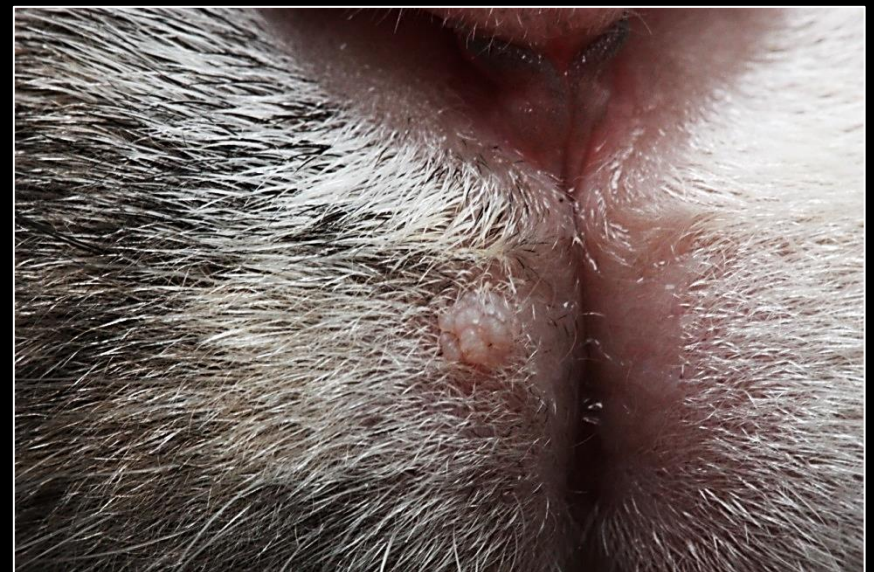
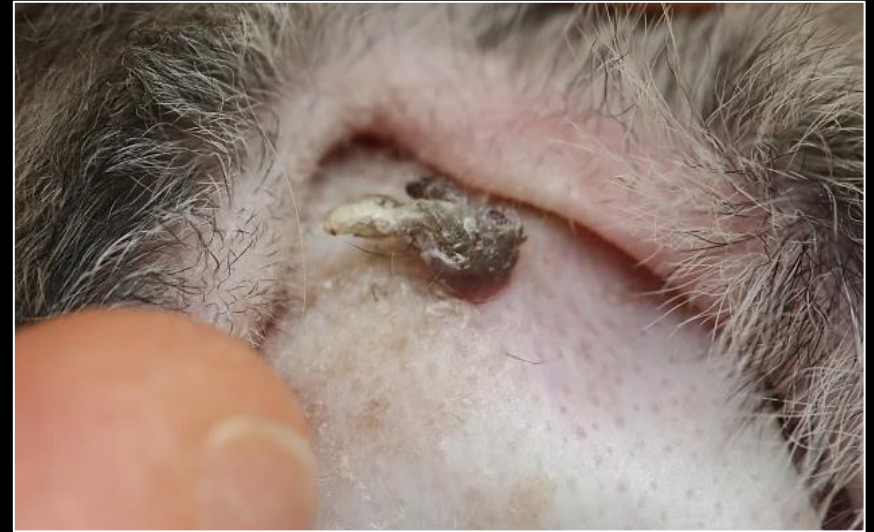Diagnosis

Characteristic skin tumors. A biopsy must be taken to determine the nature of the tumor via histopathology.

Control

In areas where the disease is endemic, control of insects is necessary.

Immunization is possible with an intraperitoneal inoculation of a glycerinated suspension of the papilloma.





Papilloma virus

Three types of papillomatosis have been identified in rabbits: oral papilloma, anal papilloma and Shope papilloma.

Oral papilloma are caused by the rabbit oral papilloma virus, belonging to the Papillomaviridae subfamily. This virus is different from the Shope papilloma virus.

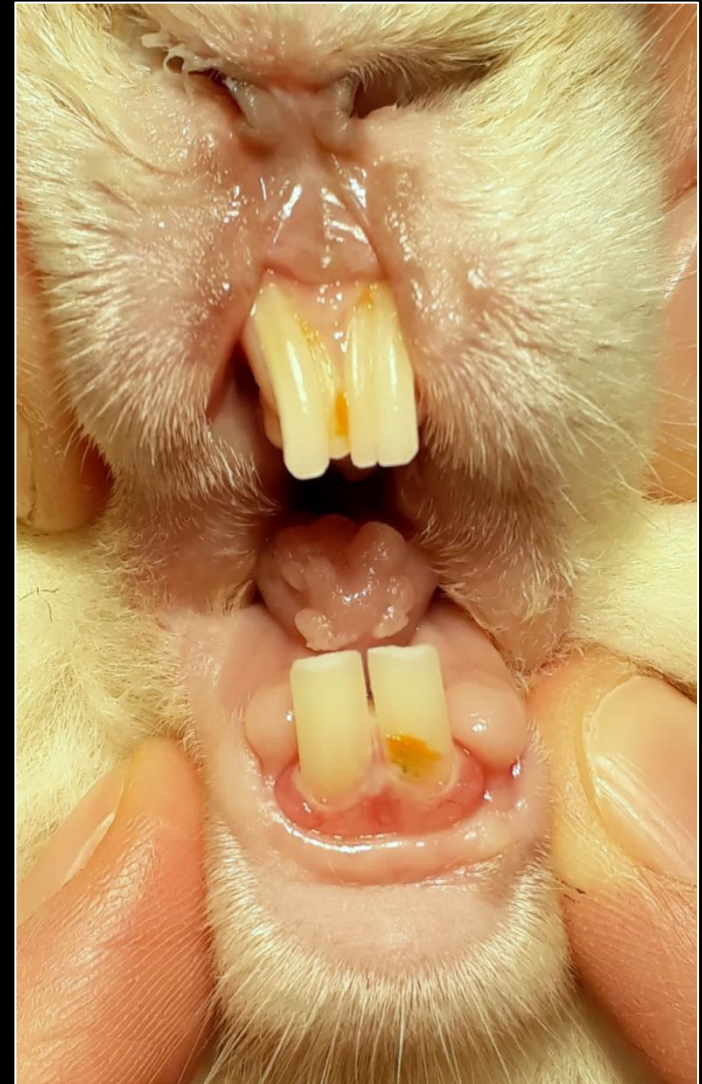




Papilloma virus

Oral Papilloma

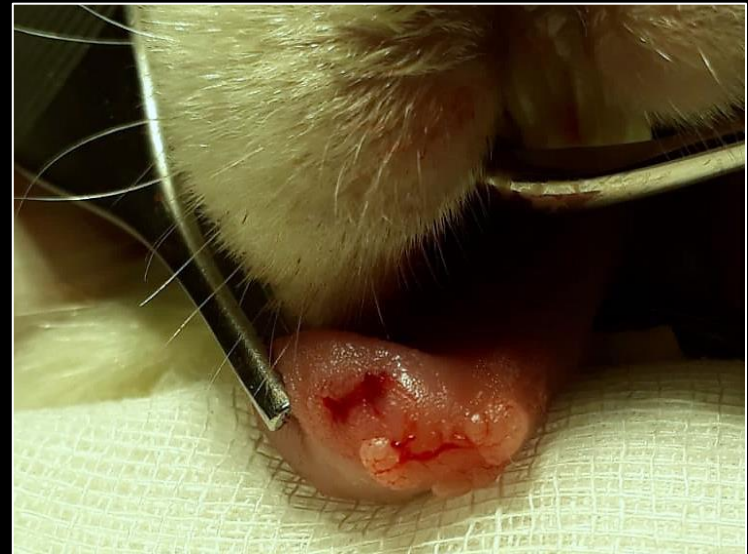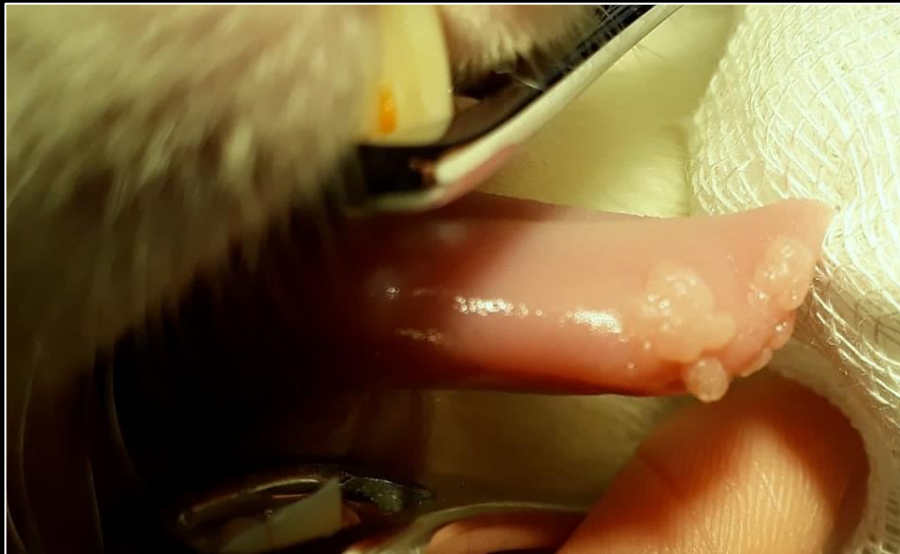- Rare and benign papillomavirus disease.
- Higher incidence in young rabbits.
- Lesions consist of small grayish-white growths or warts on the lower surface of the tongue or on the floor of the mouth.
- Soft swelling that becomes rough and ulcerated. Lesions grow during several months, than regress within weeks.
- Direct contact and development of injuries.





Papilloma virus

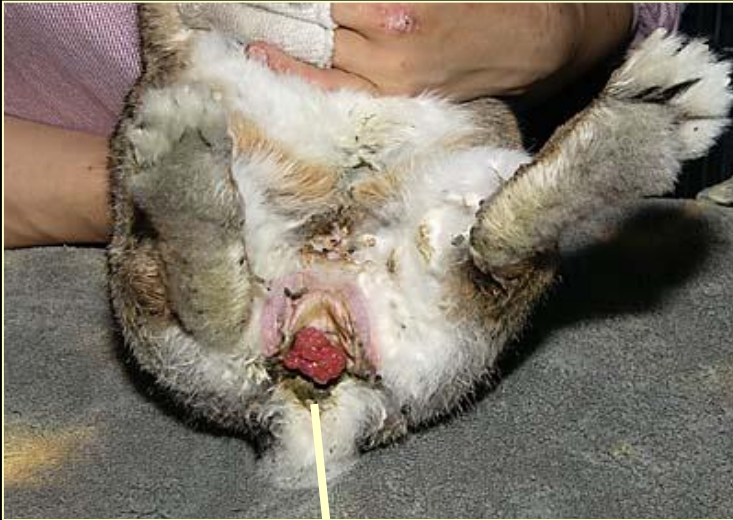Diagnosis and treatment: typical lesions in the mouth, biopsy. Surgical excision



Control: rabbits recovering from the disease are resistant to reinfection, but remain susceptible Shope Papilloma virus.



Anal papilloma



Anal papilloma are found at the junction of the rectum and the anus;

Benign tumors that develop from the squamous epithelium composed of keratinocytes;

A virus is suspected to cause anal papilloma, but could not be proven;

Size and appearance of anal papilloma vary greatly;

Tumors are vascularized. Injury or traumatism lead to great bleeding;

A cancerous transformation is not excluded;

The immune response will lead to natural regression and disappearance of the tumor.

Treatment

Complete surgical resection.



Lapine parvovirus

Lapine parvovirus

- The virus has been found in rabbits in Japan;
- Studies in the U.S. have revealed that rabbits have high antibody titers;
- Inoculation by mouth or IV causes depression and anorexia with zero mortality;
- The virus was detected in the bowel, small intestine, liver, pancreas, base, appendix and mesenteric lymph nodes;
- Rabbits develop antibodies that inhibit hemagglutination.

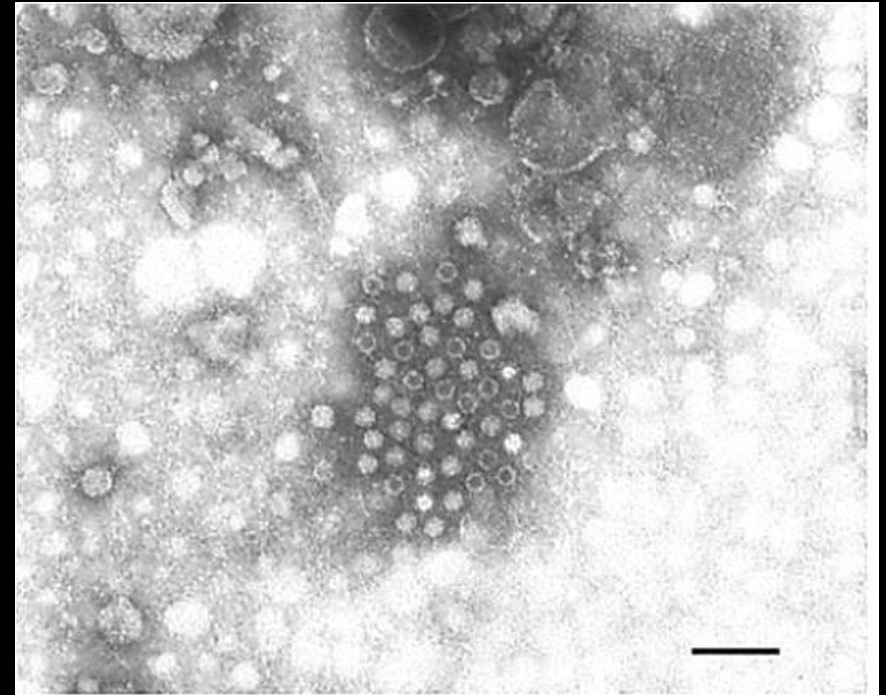
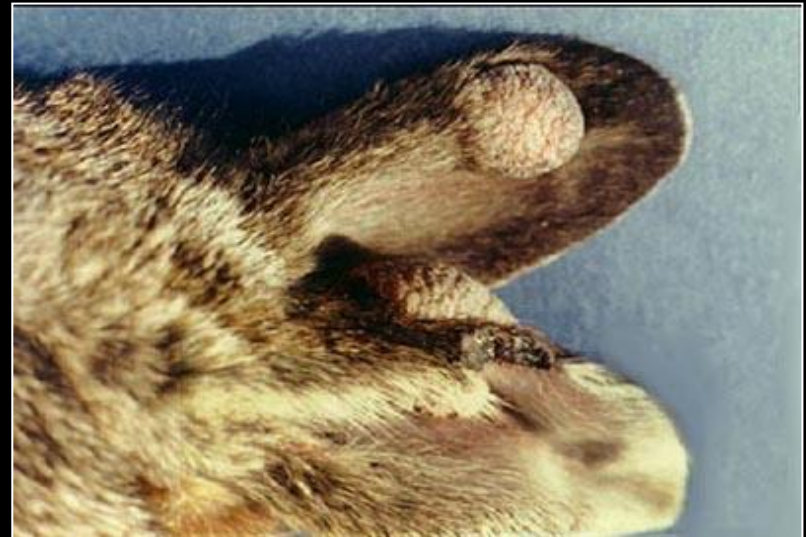
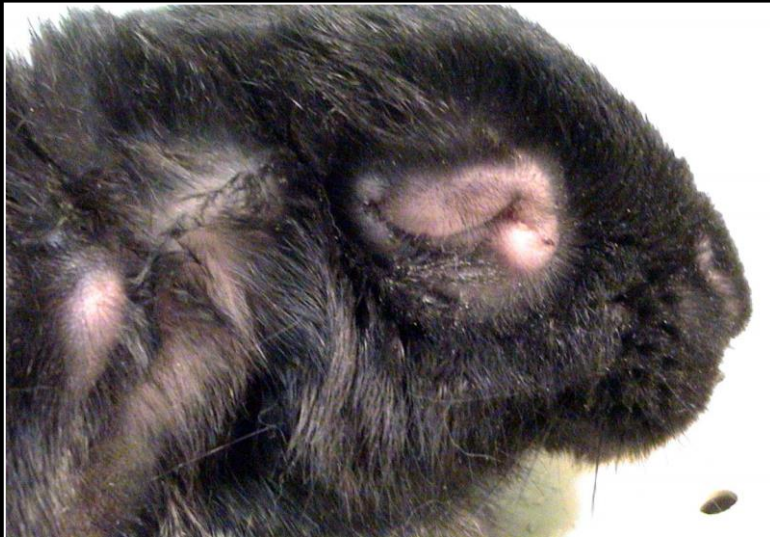
Figure 4. *Negative staining electron micrograph of rabbit parvovirus. Viral particles are clumped by using a specific hyperimmune. Bar=100nm*



Poxviridae

Poxvirus causes **Myxomatosis**, **Fibroma** and **Smallpox** in rabbits.



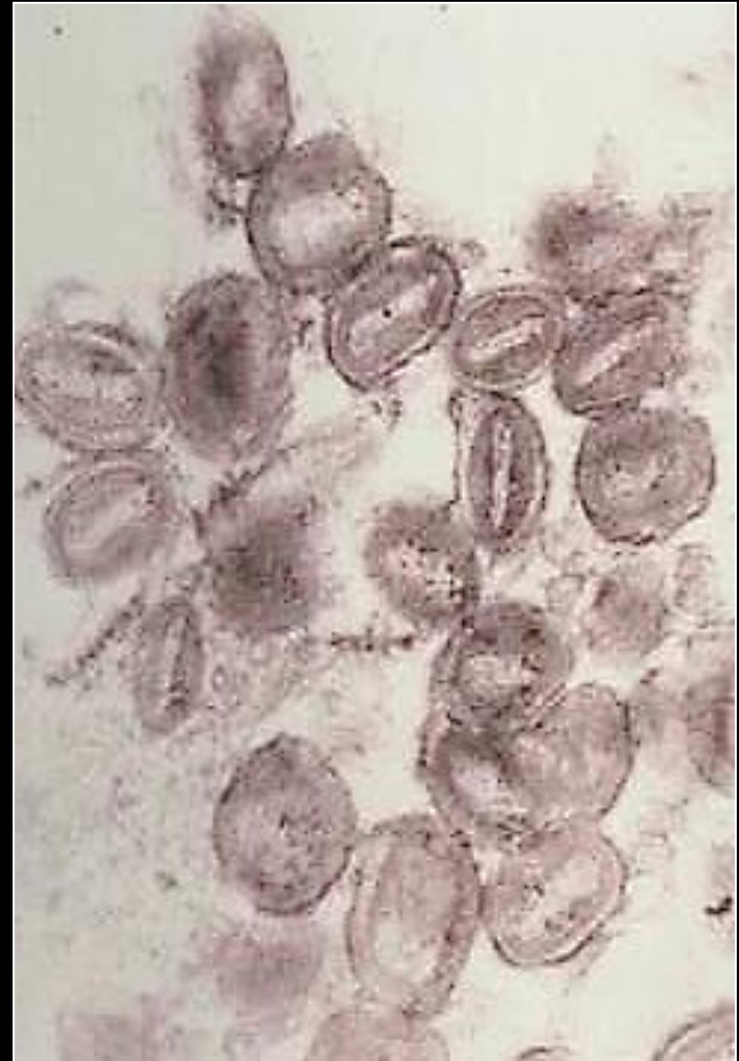


Poxvirus - Myxoma virus

- Myxomatosis disease was discovered by Sanarelli in Uruguay in 1896;
- In 1928 it was observed in the United States;
- It is endemic in: South America, North America, Europe and Australia;
- Present during the warm season;
- Transmission by direct contact or insect vectors: arthropods, mosquitoes and fleas;
- The first signs of the disease appears 3 days post-infection;

Three forms of the diseases are nowadays observed in rabbits:

- Acute myxomatosis;
- Nodular myxomatosis;
- Respiratory myxomatosis.





Acute form of myxomatosis

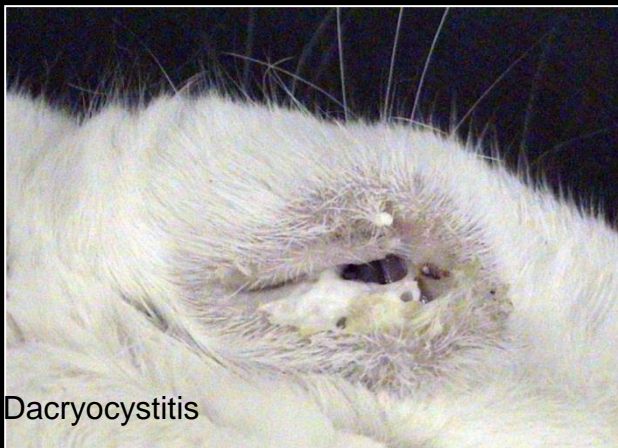Edema around the eyes, followed by the lips, genital organs and purulent conjunctivitis. Blindness and death 8 to 15 days after infection.



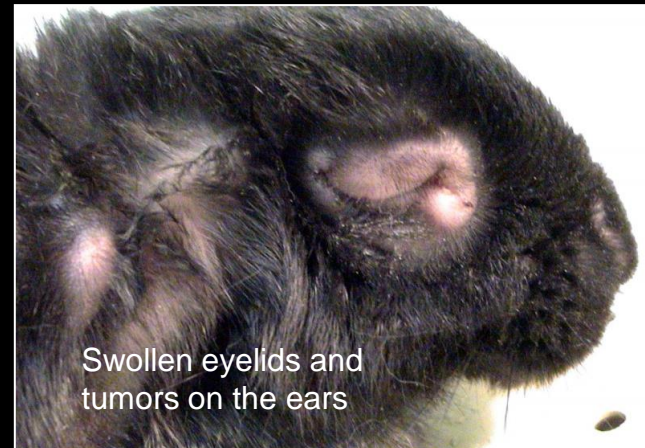
Nasal lesions and crusts



Lesions at the vulva



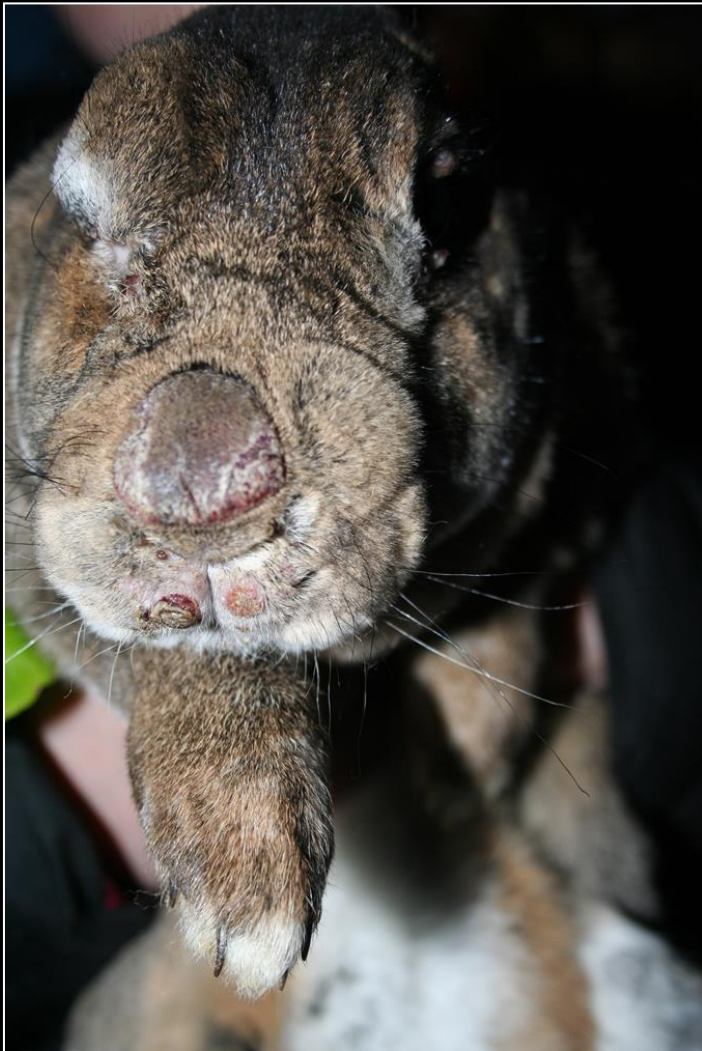Dacryocystitis



Swollen eyelids and tumors on the ears



Nodular form of myxomatosis



The nodular form of myxomatosis is observed during the summer months, when insects are numerous;
Inoculation of the poxvirus occurs during an insect bite;
Redness, papule, followed by the development of myxoma tumors on the ear pinnae, nose and extremities;
With the multiplication of the virus, more myxoma will appear on the eyelids, nose, ears and genital organs.





Respiratory form of myxomatosis



A **respiratory form of myxomatosis** has been observed in rabbitries in France:

- Difficult to differentiate from Pasteurellosis, as it presents the same symptoms;
- Myxoma or congestive macula may develop on the ears and genital organs;
- Incubation time varies between 7 to 13 days;
- First clinical signs appear up to 20 days after infection;
- This form of the disease is observed all year round;
- It is not transmitted by insects.



Myxomatosis

Diagnosis

Clinical signs is enough. In the chronic form, a biopsy of the tumor may be necessary.

Treatment

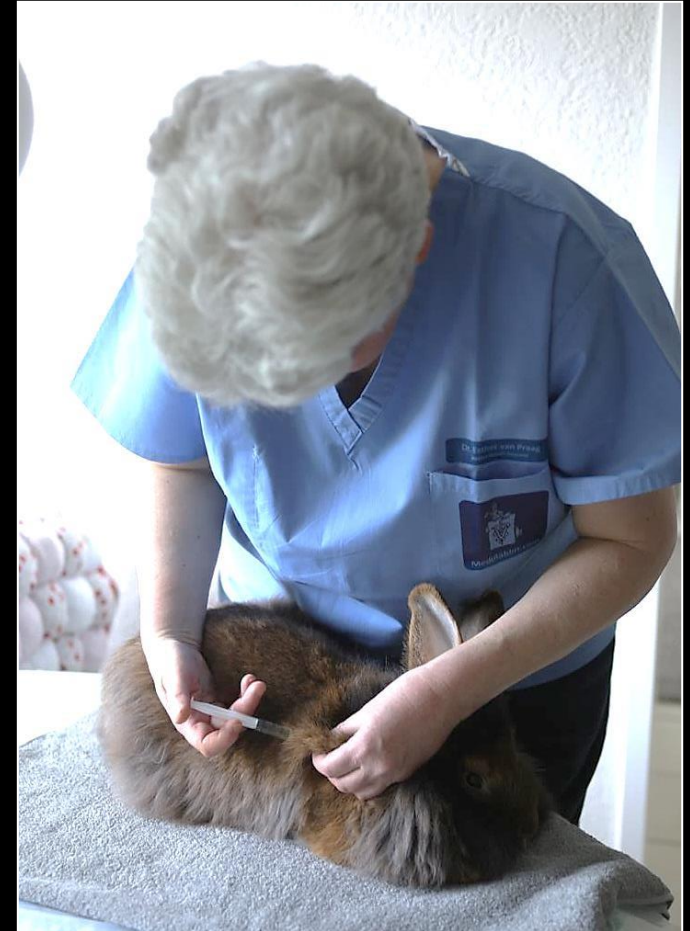
Animal must be kept in a warm area;
Ears and eyes should be cleaned regularly;
Subcutaneous fluids and syringe-feeding is possible;
Tumors can be removed by surgical excision;
Euthanasia is recommended.

Control

Protective screens to prevent blood sucking insects.

Yearly vaccination in regions where myxomatosis is endemic !!!

For instance: Nobivac Myxo-RHD vaccine



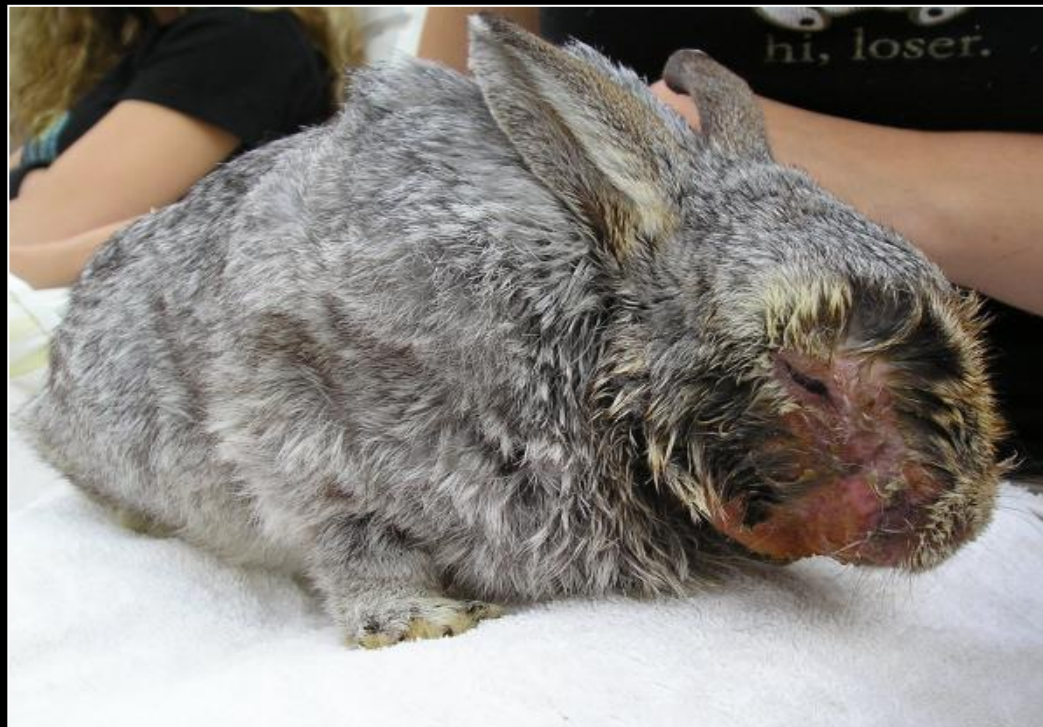

Myxomatosis vaccination: side effects

The live virus is used for vaccination against myxomatosis in Europe.

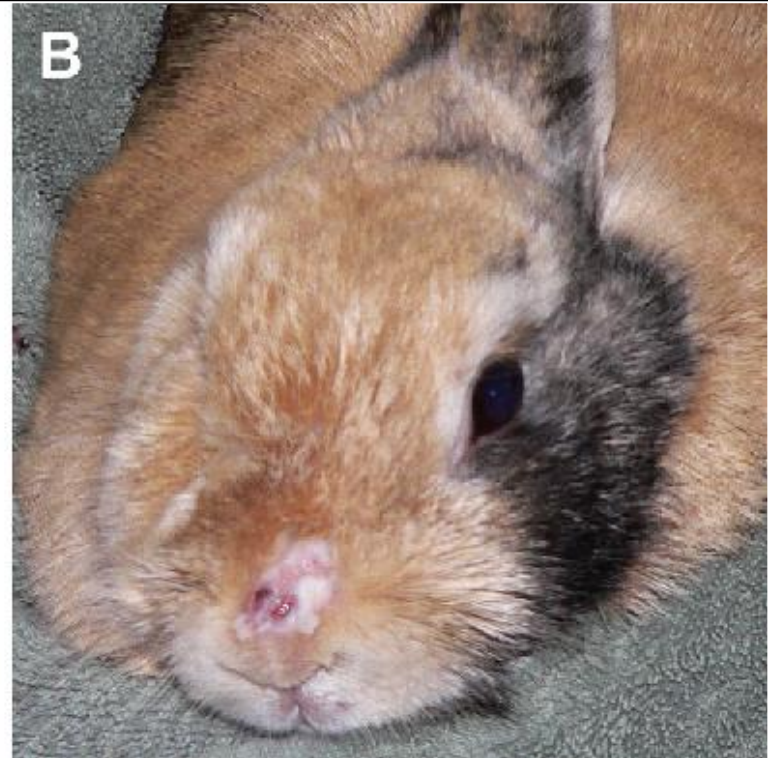
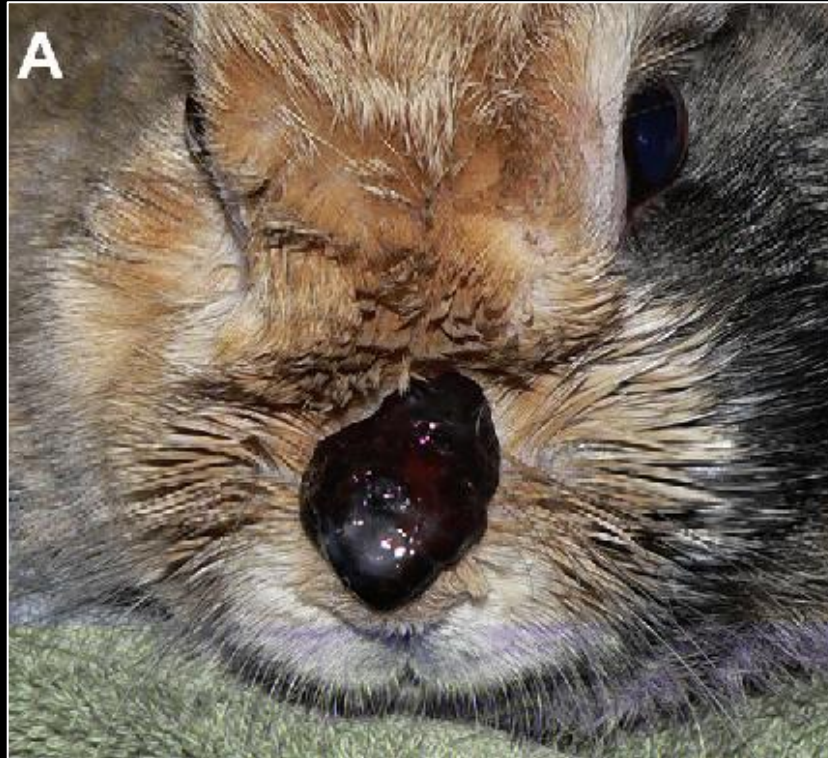Dwarf rabbits are more prone to develop a strong reaction: apathy and growth of myxoma tumors. These rabbits should only be vaccinated with the homologous form of the vaccine.

In rare cases, myxomatosis develops. The rabbit has to be euthanized. This is observed mainly after a first vaccination in older animals.





Myxomatosis vaccination: side effects



Atypical form of myxomatosis in a previously vaccinated rabbit.
The only clinical sign is a scabbing lesion developing on the bridge of the nose, which eventually sloughed.



Poxvirus – Shope fibroma virus


The **Shope fibroma virus** has been discovered in 1931 in wild cottontails. It rarely affects domestic rabbits. Transmission by insects that suck blood.

Signs

Skin lesions called fibromas;
A fibroma can form on every part of the body: limbs and feet, face, nose, eyes and back;
The growing tumor can invade muscle tissue;
Shope fibroma must be differentiated from myxoma and papilloma tumors.

Diagnosis

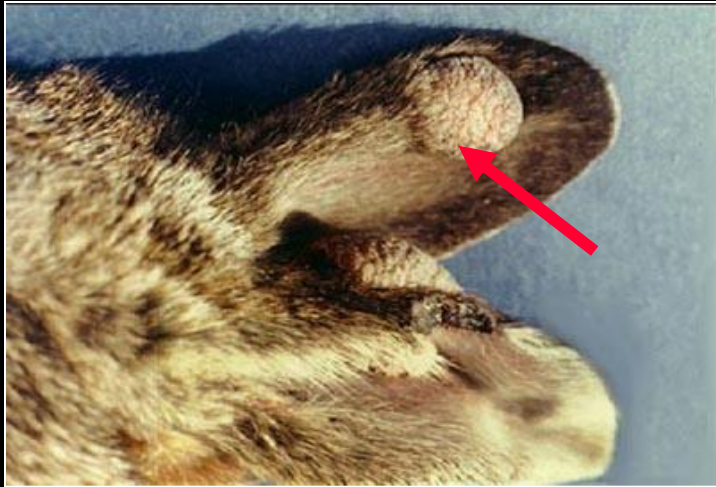Based on clinical signs and confirmed with biopsy.



Fibroma in a dwarf rabbit



Shope fibroma virus



Treatment

Surgical excision is not advised due to the high rate of recurrence.

Vector control

Protective screens to prevent blood sucking insects.

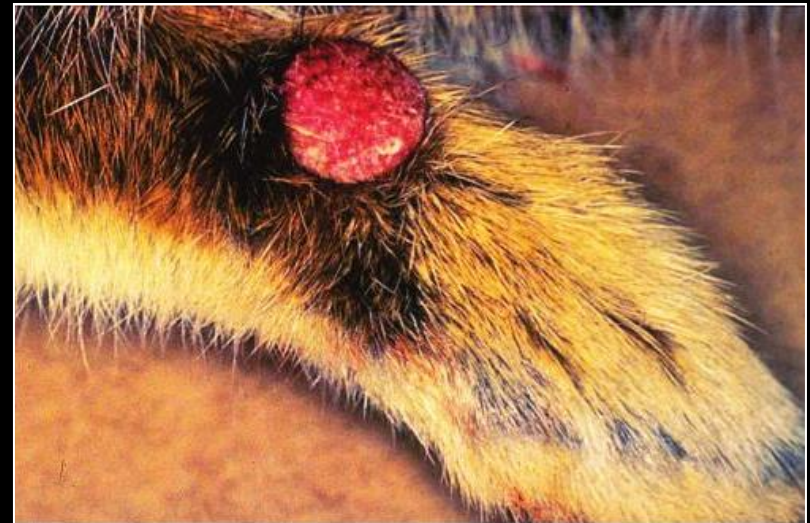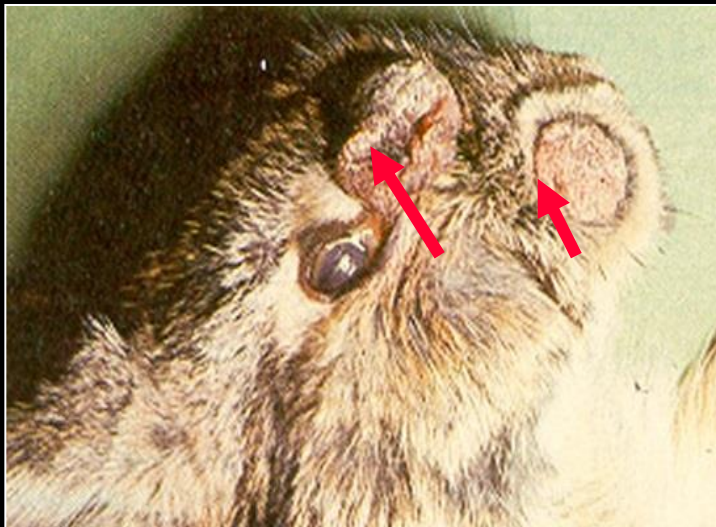


FIG. 6.19. Nodular fibroma on the forelimb of a *Sylvilagus* rabbit naturally infected with Shope rabbit fibroma virus.



Orthopoxvirus I: rabbitpox (Vaccinia)

Orthopoxvirus belong to the family of Poxviridae. It causes **rabbitpox**, also called smallpox of rabbits.

The disease was first diagnosed at Rockefeller, New-York, in 1932.

Highly contagious and with high mortality, especially in young rabbits and pregnant does;

Transmission through direct contact or inhalation.

The virus infects and multiplies in the nasal mucosa, then migrates to lymph nodes of the respiratory tract and lungs.

Signs

- Edema of the face and oral cavity;
- Fever and profuse nasal discharge;
- Erythematous rash, followed by the development of skin nodules;
- Enlargement and hardening of lymph nodes;
- In severe cases there is bleeding from the skin.





Orthopoxvirus II: Pockless rabbitpox (Vaccinia)

Spontaneous outbreak of pockless smallpox in the Netherlands.

Signs

- Fever, anorexia and lethargy;
- Blepharitis, purulent conjunctivitis and acute keratitis with corneal ulcer;
- Males develop severe orchitis with scrotal edema, papules on the foreskin and urethra in male rabbits;
- Urinary obstruction is possible;
- Similar affections in female rabbits;
- Pregnant females abort;
- Death 7-10 days later.

Diagnosis

Characteristic clinical signs and microscopic lesions.

Antibody fluorescence and tissue smears.

Control

As the natural source of this virus has not been determined, no control measures have been developed.



RNA viruses: Astrovirus
Borna virus
Calicivirus
Coronavirus
Rotavirus

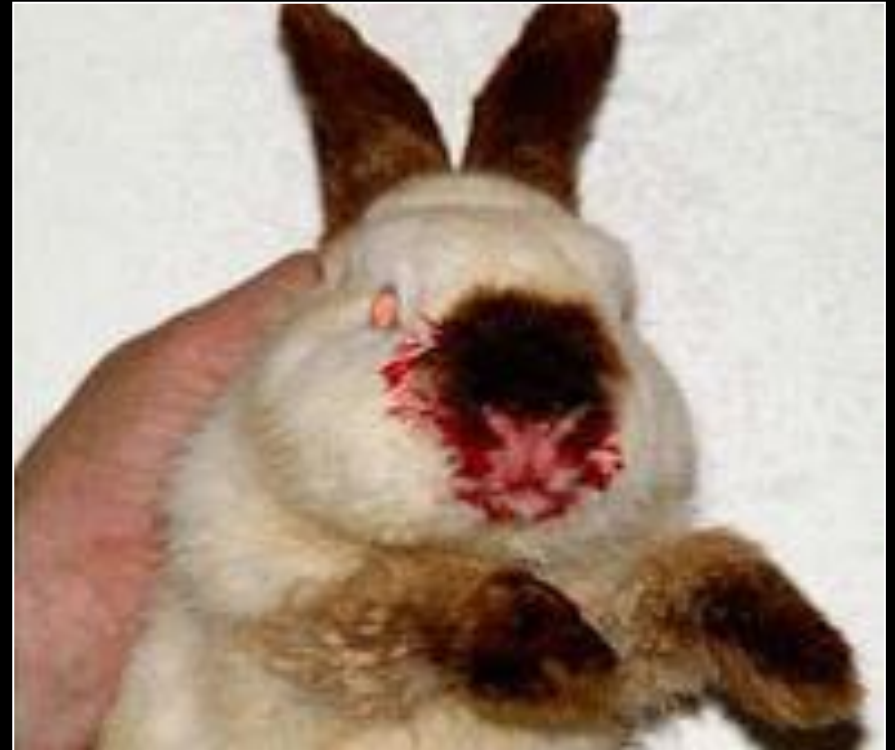

RNA viruses:	Astrovirus	Enteritis, in association with other pathogens
	Borna virus	Multifocal retinopathy, meningitis, encephalomyelitis
	Calicivirus	Rabbit hemorrhagic disease (RHDV) Rabbit calicivirus (RCV) Michigan Rabbit calicivirus (MRCV)
	Coronavirus	Rabbit Vesivirus Rabbit enteric coronavirus Pleural effusion/cardiomyopathy virus



Calicivirus

- It was first described in China in 1984.
- Within a few years, it reached Europe and caused the largest mortality of wild and domestic rabbits.
- It was named **Rabbit Viral Hemorrhagic Disease** (VHD/RDH).
- The virus has been reported as a picornavirus, or parvovirus. It is a calicivirus of the genus Lagovirus.
- Nucleic acid sequence comparisons reveal homology with **feline calicivirus**.
- The virus does not agglutinate erythrocytes in rabbit, unlike man.
- It affects rabbits more during the warmer season.



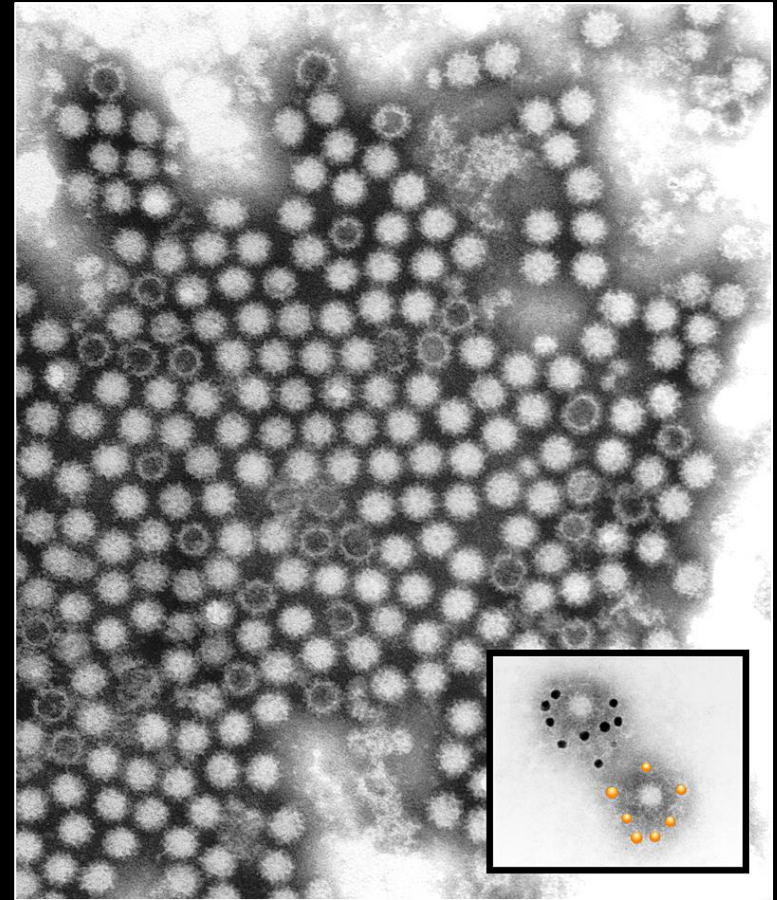


Rabbit hemorrhagic disease (RHDV)

- **VHD1** (RHD1) affects rabbits older than 2 years, young animals are not clinically affected.
- **VHD2** (RHD2) affects all rabbits, including young animals. It affects also other Lagomorphs, e.g. hares and cottontails.
- Lactating and pregnant females are particularly susceptible.

Transmission is horizontal:

- Fecal-oral route;
- Fomites, e.g., water pipes, eating dishes utensils, on clothing and hands;
- Aerosol;
- Blood sucking insects;
- Secretions and excretions.



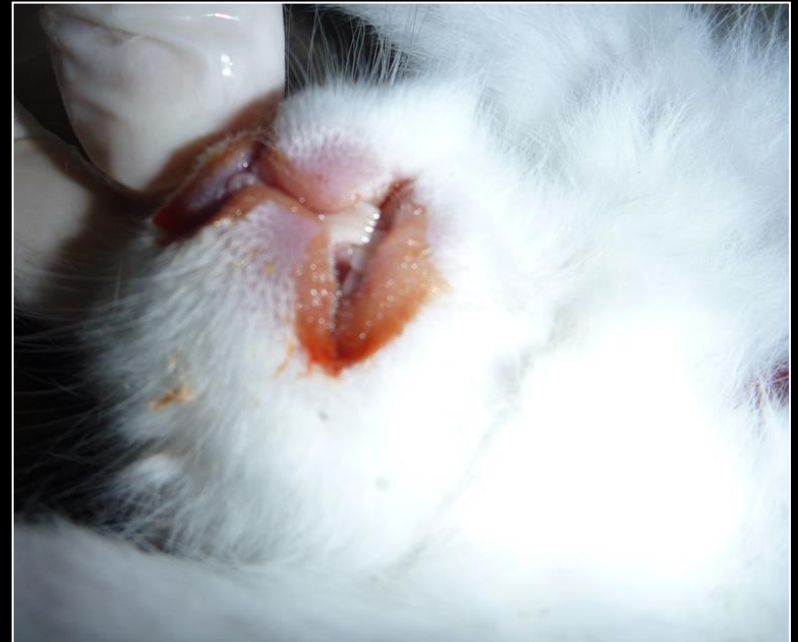CSIRO ScienceImage 2009 Rabbit Calicivirus



Rabbit hemorrhagic disease (RHDV)

- The virus enters the body through the conjunctiva, nasal passages, and traumatized tissue;
- Disease course is acute and rapid. Incubation time is fast: 1-2 days,
- Due to the rapid course of the virus the signs are not noticed and rabbits are often found dead,
- Highly infectious;
- High morbidity and mortality.

Clinical signs: Depression;
Lethargy;
Anorexia;
Tachypnea;
Cyanosis;
Abdominal distension;
Constipation or diarrhea.

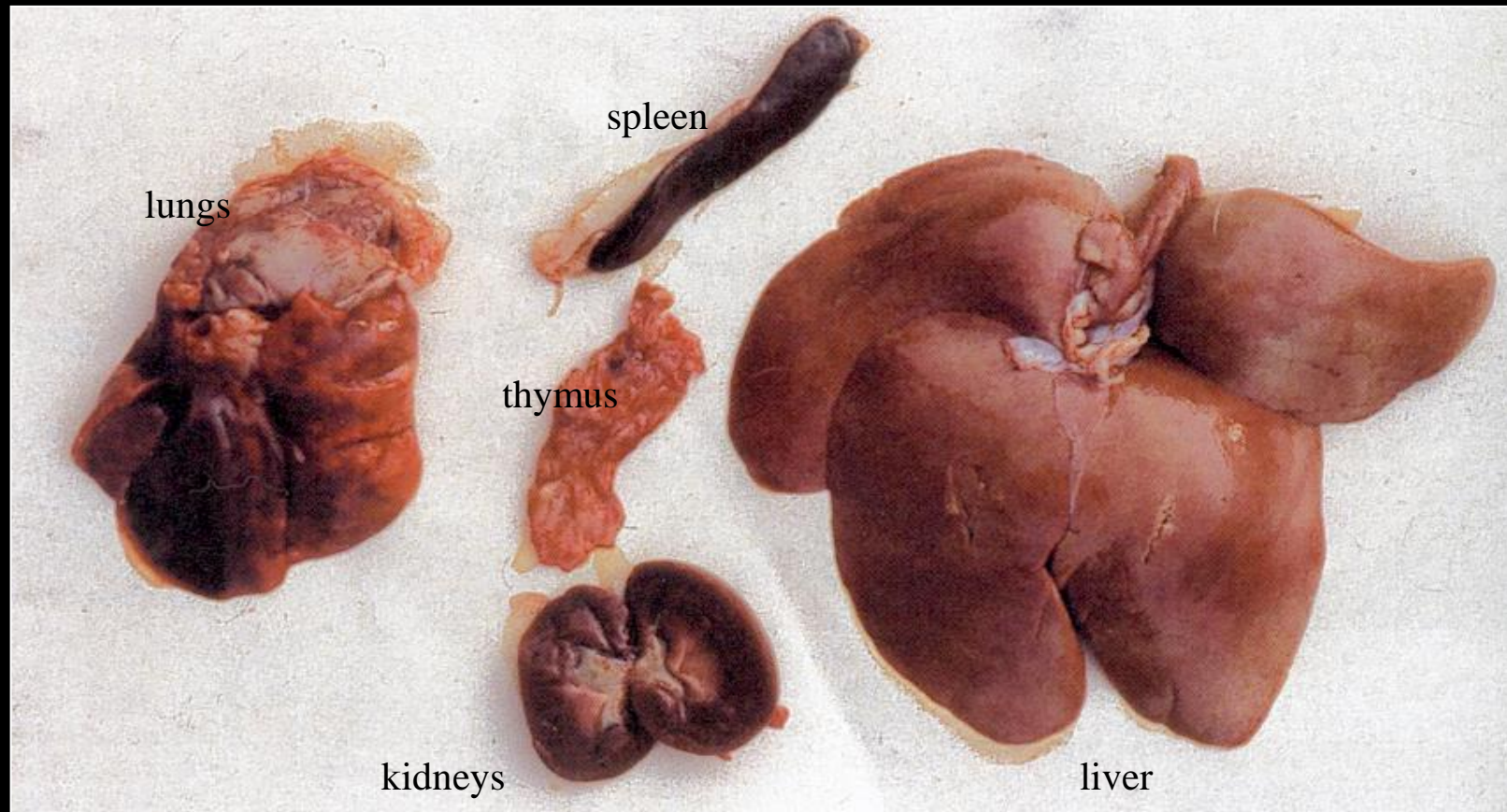


In the final stage of the disease, the rabbit becomes hypothermic and recumbent, with seizures , epistaxis (nosebleed).



Rabbit hemorrhagic disease (RHDV)

The VHD calicivirus causes major damages to the rabbit's internal organs such as the liver and gut.





Rabbit hemorrhagic disease diagnosis

Hemagglutination test: liver, lungs, and kidneys.

Necropsy: Congestion and hemorrhages in various organs, but especially in the lungs. Liver looks pale and periportal necrosis is observed.

Histology: Coagulation and focal liver necrosis, disseminated coagulation in the kidney, lungs with hemorrhages in the alveoli.

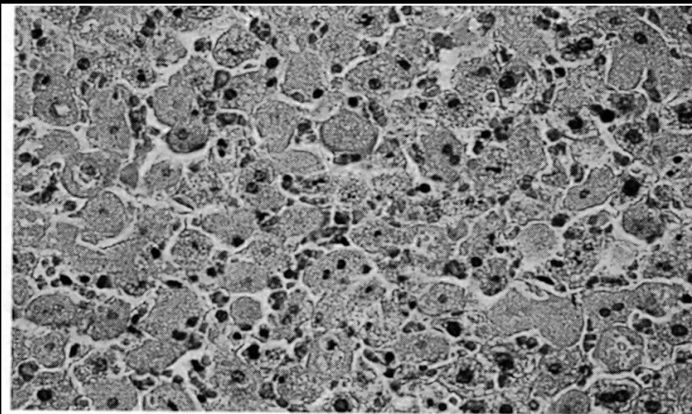


FIG. 6.9—Section of liver from a fatal case of rabbit hemorrhagic disease in a feral *Oryctolagus* rabbit from Australia. Note the vacuolation of hepatocytes and the striking dissociation of hepatic cords. (Courtesy M. Kabay, Animal Health Laboratories, Agriculture Western Australia)

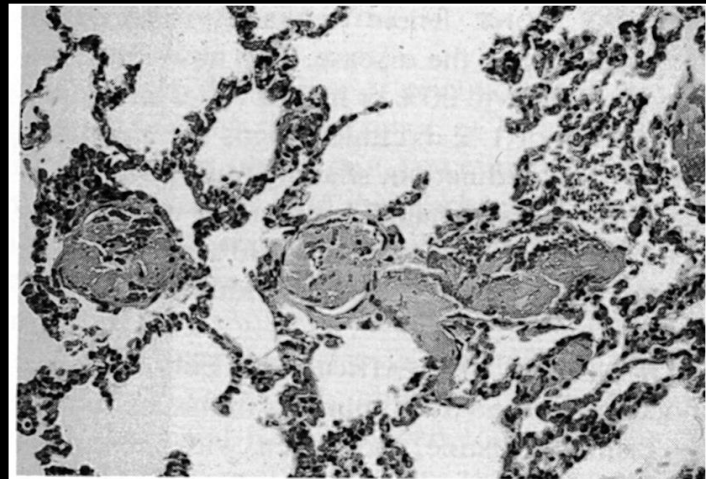


FIG. 6.10—Section of lung from the same animal as in FIGure 6.9. Note the multiple thrombosed vessels. (Courtesy M. Kabay, Animal Health Laboratories, Agriculture Western Australia)



Rabbit hemorrhagic disease protection

1995: Laboratory accident in southern Australia,
The virus escaped from quarantine and killed 10 million rabbits in 8 weeks.

Control

- Restricted access;
- Disinfection of instruments, cages and equipment (sodium hypochlorite 0.5%, formalin 1%);
- Rabbits that come from areas with VHD must go through a quarantine of at least 1 month;
- Colonies of rabbits should be euthanized, as the virus can remain in rabbits for 1 month;
- **Yearly vaccination of rabbits against VHD1 (RHD1) and VHD2 (RHD2) !!!!**



Rabbit hemorrhagic disease vaccines



RHD1

Nobivac Myxo-RHD solution is only against RHD1

RHD2

FILAVAC VHD K C+V vaccine

or

Eravac vaccine

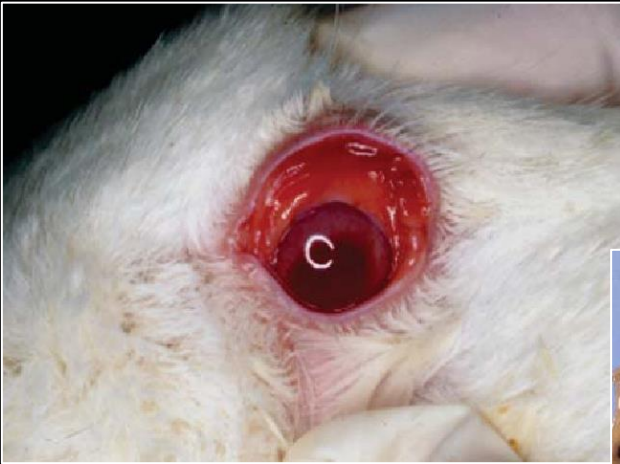
or

Nobivac Myxo-RHD PLUS vaccine

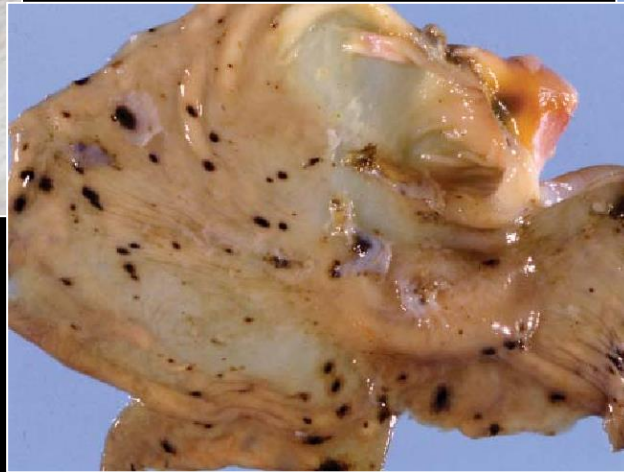


Michigan Rabbit calicivirus (MRCV)

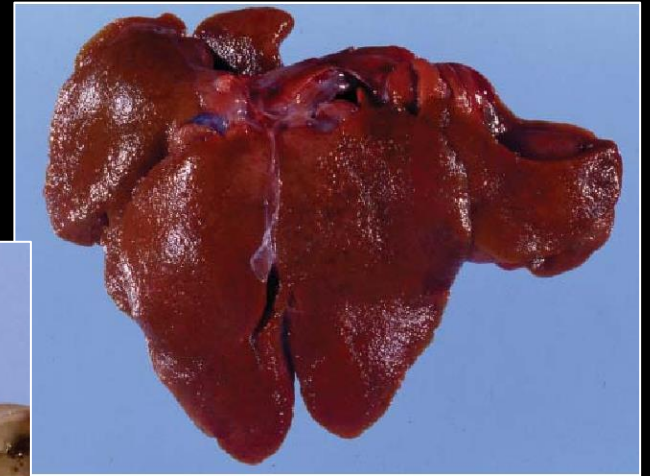Rabbit calicivirus distinct from rabbit hemorrhagic disease virus;
It is a new variant of the nonpathogenic rabbit calicivirus (RCV);
It is characterized by a low pathogenicity;
Viral RNA has been found in the liver rather than in the intestine.



Conjunctival erythema in affected doe.



Multifocal gastric hemorrhage in affected rabbit.



Liver of affected rabbit with granular texture, accentuated lobular pattern, and multifocal capsular petechiae.



Rabbit Vesivirus

Newly discovered rabbit calicivirus in young rabbits in Spain and in Oregon;

It causes enteritis and severe diarrhea;

It is suspected that concurrent infection of vesivirus with pathogenic bacteria (*Clostridium* sp. or *Escherichia coli*) results in a more severe and fatal form of the infection.



Coronavirus

Rabbit coronavirus (RbCoV) was first encountered in 1961 in Scandinavia and has been first described in 1968.

This agent is an unassigned member in the Coronavirus genus.

It exists in two pathologic forms in rabbit: a systemic disease (pleural effusion disease or cardiomyopathy of rabbit) and an enteric disease.

Signs Fever;
 Anorexia;
 Weight loss;
 Tachypnea;
 Inflammation of the iris of the eye (iritidocyclitis).

Diagnosis

It has only been reported in laboratory rabbits inoculated with the virus, so its existence is measured by the signs that the animal presents.

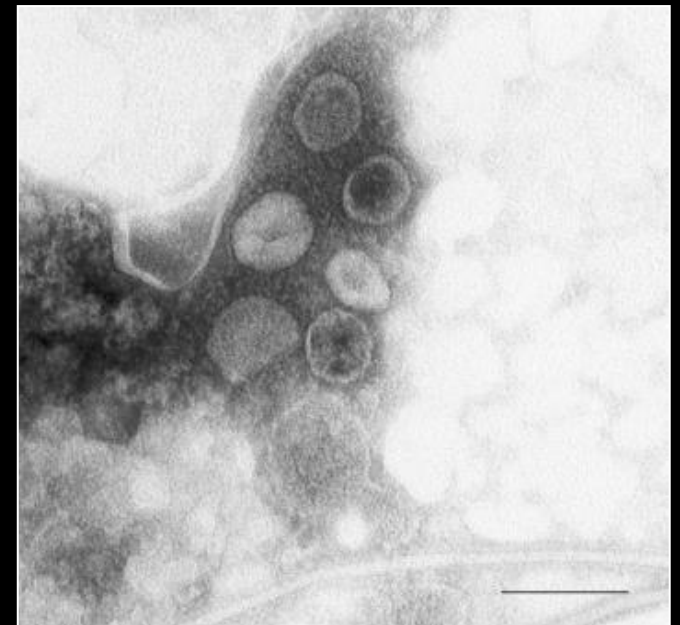


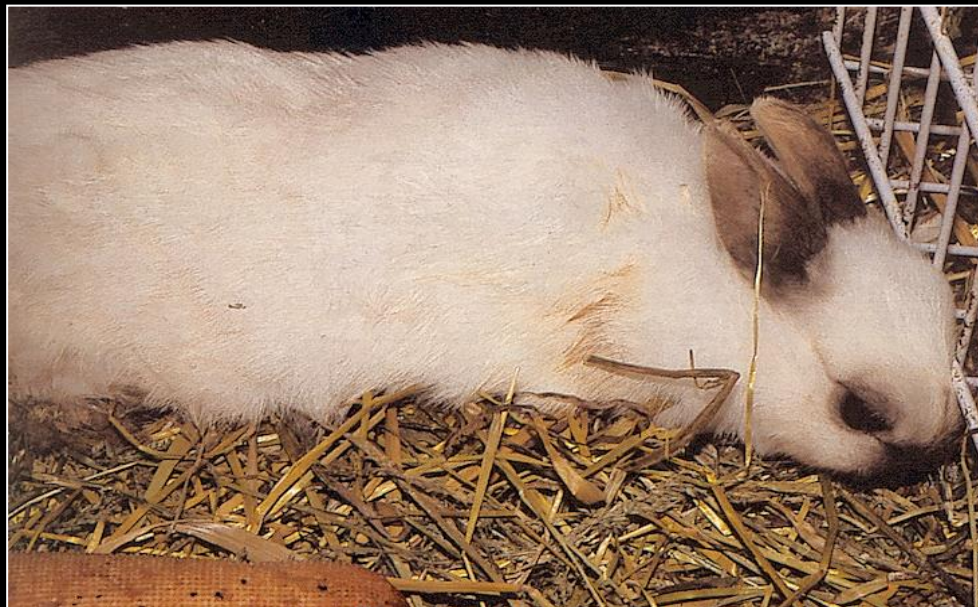Figure 2. *Negative staining electron micrograph of rabbit coronavirus particles. Bar=200nm*



Rabbit Enteric Coronavirus (RbCV)

Rabbit Enteric Coronavirus

- Discovered in 1980 in Canada;
- Present in rabbit feces;
- The virus affects mainly rabbits at the age of 3 to 10 weeks of age;
- The virus has been diagnosed in adult rabbits;
- High mortality and morbidity.



A severely dehydrated rabbit, suffering from viral enteritis.



Rabbit Enteric Coronavirus (RbCV)

Clinical signs of Rabbit Enteric Coronavirus

- Lethargy;
- Diarrhea;
- Abdominal pain;
- Death.

Diagnosis

- Based on clinical signs;
- Autopsy and histopathological analysis, as well as agglutination of the feces.

Histopathology

- Large and small intestine with diffuse inflammatory cells and mucous edema.
- Distended cecum filled with watery fluids.

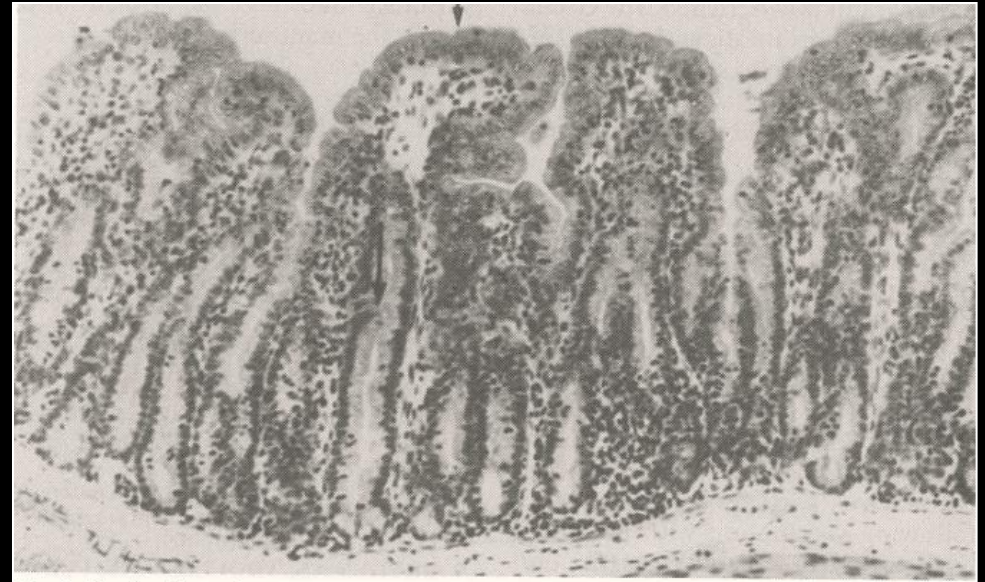

Fig. 4. Section from the small intestine of an infected rabbit showing clinical signs of diarrhea. Hypertrophy of the intestinal crypts are observed (→). Immature enterocytes lining the intestinal villi are cuboidal or low columnar with basophilic cytoplasm (→). H&E. X530.



Pleural effusion Coronavirus

Pathology

Pulmonary edema;

Pleural effusion;

Cardiomyopathy;

Dilatation of the right ventricle;

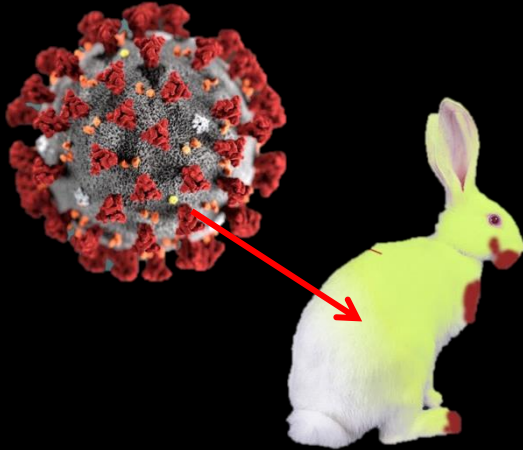
Hepatosplenomegaly and congestion of lymph nodes.

Necropsy shows effusion of the pleura, but it was later discovered that it mainly affected the heart.



COVID-19 Coronavirus

Wild and pet animals may be at risk of COVID-19 infection.



Hong-Kong: A very low level of the virus has been detected in a dog, which did not support an active infection. A risk of transmission cannot be excluded.

Germany: a large scale study has shown that pet animals can be carriers of the viral ARN, but not of the life virus (April 2020).

Belgique: **First known case of a cat infected by COVID-19 coronavirus, confirmed by the veterinary medicine faculty in Liège (March 2020).**

New-York: **Tigers of the Zoo of New-York have been tested positive and developed coughing and respiratory problems (April 2020).**



Rotavirus

Isolated from rabbits with severe diarrhea in 1976.

Affects mainly young rabbits between 30 and 80 days of age.

Rabbit rotavirus is mildly pathogenic.

Concurrent infection of rotavirus with pathogenic bacteria (*Clostridium* sp. or *Escherichia coli*) results in a more fatal disease.

Almost 100% of the adult rabbits in commercial rabbitries and breeders have antibodies against rotaviruses, as compared to 30% only in wild rabbits.

Antibodies to the virus, as well as the virus, are excreted in the feces and are therefore transmitted via the fecal-oral route.

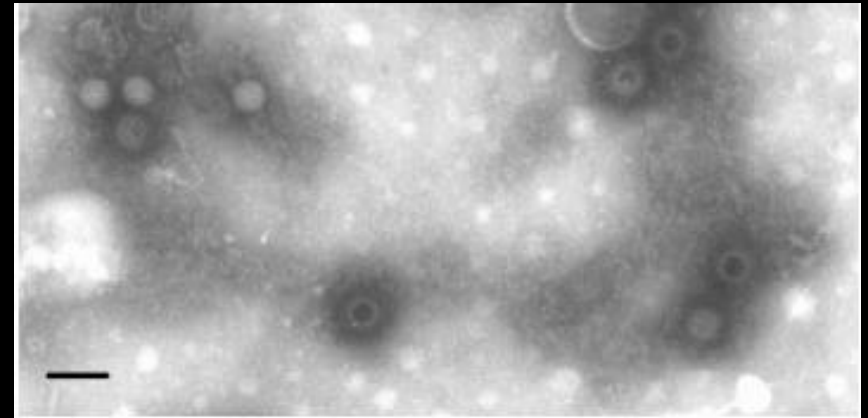


Figure 1. *Negative staining electron micrograph of rabbit rotavirus. Full and empty particles are visible. Bar=100nm*



Rotavirus



Signs

- Mucous or watery diarrhea;
- Anorexia;
- Dehydration;
- Congestion and distension of the intestines and cecum.

Diagnosis

- Isolation of the virus from the feces, Demonstration of antibodies;
- Use of ELISA tests.

Differential

Other causes of diarrhea must be ruled out: *Escherichia coli*, *Clostridium* sp, protozoa, intestinal parasites, contaminated food, intoxication, etc.



Rotavirus

Treatment

Supportive care with fluids, antibiotics to prevent secondary infections.

Infected rabbits shed the virus during 7 days = Stop of breeding for 4 to 6 weeks, to allow the disease to run its course.

For prevention and control of this virus, "stress" should be reduced, together with the appropriate treatment and hygiene should be improved on site.

Necropsy

Congestion and distension of the intestines and cecum;

Small hemorrhages (petechia) in the small intestine and colon.

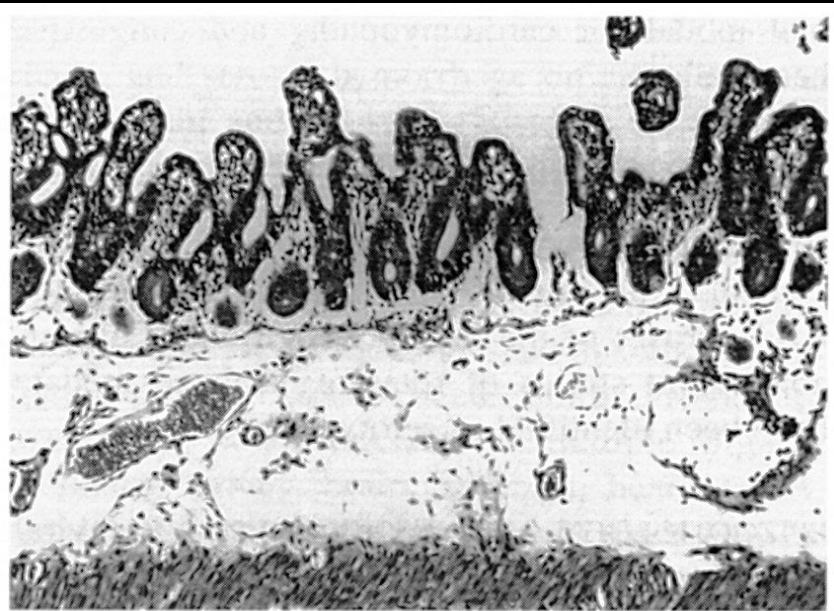


FIG. 6.11—Section of small intestine from young rabbit with a confirmed epizootic of rotaviral enteritis. There is blunting and fusion of villi. Enterocytes lining villi are cuboidal and poorly differentiated. (Courtesy T.R. Schoeb)



References

Bergin IL, Wise AG, Bolin SR, Mullaney TP, Kiupel M, Maes RK. Novel calicivirus identified in rabbits, Michigan, USA. *Emerg Infect Dis.* 2009;15(12):1955–1962.

Dean H. Percy and Stephen W. Barthold, *Pathology of Laboratory Rodents and Rabbits*, Iowa State University Press, 2001,

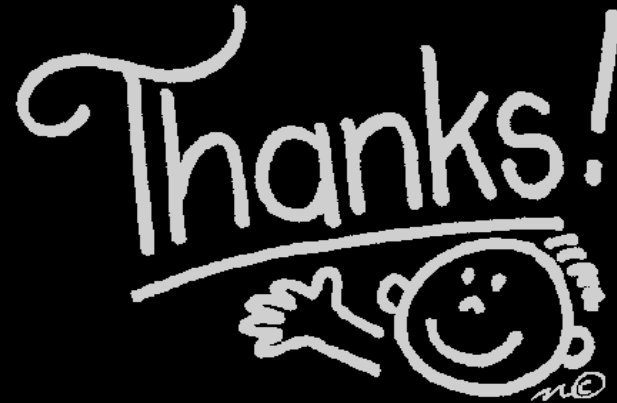Descôteaux JP, Lussier G. Experimental infection of young rabbits with a rabbit enteric coronavirus. *Can J Vet Res.* 1990;54(4):473–476.

Jin L, Valentine BA, Baker RJ, Löhr CV, Gerlach RF, Bildfell RJ, Moerdyk-Schauwecker M. An outbreak of fatal herpesvirus infection in domestic rabbits in Alaska. *Vet Pathol.* 2008 May;45(3):369-74.

Maertens, L.; Coudert, P., *Recent advances in rabbit sciences*, ILVO ed. Melle (Belgium)
Patrick J. Manning, Daniel H. Ringler and Christian E. Newcomer, *The Biology of the Laboratory Rabbit*, New York: Academic Press, 1994,

Susan E. Aiello (Editor), Asa Mays (Editor), *Merck Veterinary Manual*, Merck & Co, Merial Limited, Merck & Co, 8th ed, 1998,

Samuel Boucher et Loïc Nouaille, *Maladies des lapins*. France Agricole, 2002.



to

- Dr. Katleen Hermans** Kliniek voor Pluimvee en Bijzondere Dieren, University of Gent, Belgium, for her pictures of various viral and bacterial rabbit diseases.
- Akira Yamanouchi** VEIN (Veterinary Exotic Information Network, <http://vein.ne.jp/>), Japan, for the pictures of various viral and bacterial rabbit diseases.
- Denise Baart** for the picture of her sick rabbit, The Netherlands.
- Janet Lacey** for her pictures of nodular myxomatosis.
- Marjorie Panchaud** and her rabbit rescue "Les lapins du Cœur».
- Arie van Praag** for his help in taking pictures of rabbit diseases.