



**MediRabbit.com**

## **Toxoplasmosis, an unrecognized parasitosis in rabbits**

**Esther van Praag**

**Rabbits with a positive titer for *Encephalitozoon cuniculi* are often also positive for *Toxoplasma* sp. (Neumayerová et al., 2014). Is this the reason why the benzimidazole treatment against *E. cuniculi* is not always effective in rabbits, while that with pyrimethamine against *Toxoplasma* sp. work in some rabbits ?**

Already in 1908, Splendore discovered that rabbits can be infested by the protozoan parasite and agent of

toxoplasmosis. He named it *Toxoplasma* sp. due to its crescent shape: "toxon", Greek for crescent, and "plasma" meaning shape.



**Figure 1:** Even when cohabitation between a cat and a rabbit is excellent, there is a risk of transmission of the toxoplasmosis parasite (Photo courtesy of Denise Devoto)



**Figure 2:** Cats are the definitive host of *Toxoplasma gondii* and free oocysts in its environment with feces, independently of living outside or inside. (Photos courtesy of Norman Bowdler (top) et Denise Devoto (bottom))





**Figure 3:** Friendship between a cat and a rabbit comes at the price of a strict hygiene. (Photo courtesy of Aveleira Hayzel Silohcin)


Wild and domestic rabbits and a few hare species infested by *Toxoplasma* sp. have been found all around the world (Cox et al., 1981 ; Dubey et al., 2011 ; Gustafsson et al., 1997a, b, 1997a ; Kapperud, 1978 ; Lainson, 1955). The anthro-po-zoonotic transmission potential of the parasite could not be established with certainty to this day, and should not be minimized. Indeed, a pet rabbit with facial and cervical masses and a high titer for anti-toxoplasma antibodies is suspected to have transmitted cervical toxoplasmosis to its owner (Ishikawa et al., 1990). High levels of anti-toxoplasma antibodies have also been detected in hunters of wild rabbits and hares (Beverley et al., 1976). Further studies suggest that farm rabbits suffering from toxoplasmosis of the central nervous system may have transmitted the parasite to persons who took care of them (Sroka et al., 2003). It remains, however, hard to establish a direct link between rabbits and man when cats are sharing the same environment than rabbits. (Figures 1, 2, 3, 4, 5).

### Causing agent

*Toxoplasma gondii* is an ubiquitous

obligate, intracellular parasite that belongs to the class of Coccidia. It infests mammals, birds as well as man. The life cycle of this parasite is complex, with sexual and asexual stages, and it needs a wide range of intermediate hosts and a definitive host to develop. It can have 3 different infecting forms according to its host:

- Oocysts in the definitive host. This phase includes sexual reproduction. Oocysts are released in the environment with feces of the definitive host, e.g. cats. Thanks to a resistant membrane, oocysts can survive difficult environmental conditions. This permits the development of sporozoites located in the oocysts. After ingestion, oocysts get into the intestine of an intermediate host, including rabbits, and 4 sporozoites will be freed. These will cross the intestinal membrane and will



**Figure 4:** Neurological anomalies should be taken seriously when a rabbit lives with a cat. (Photo courtesy of Piper Provost)

spread throughout the body via the blood and lymphatic circulatory systems. They migrate into cells of the reticulo-endothelial system in order to multiply and transform into tachyzoites.

- ***Tachyzoites*** in the intermediate host. They have a crescent shape and measure between 4-8  $\mu\text{m}$  long and 2-3  $\mu\text{m}$  large. This free and proliferative phase of the parasite induces the acute form of the disease. In rabbits, tachyzoites have been observed inside and outside cells. The asexual proliferation of tachyzoites inside host cells is fast; it causes the lysis of cells and damages to affected tissues. The migration of tachyzoites into the blood or lymphatic circulatory systems leads to the spreading of the parasite throughout the body and their migration to muscular and nervous tissues. At this stage, the immune system of the host is activated and will prevent the multiplication of the tachyzoites. The latter will transform into bradyzoites.
- ***Bradyzoites*** in the intermediate host. They are located in cysts that measure between 5 à 50  $\mu\text{m}$  of diameter, present in various tissues. This is the quiescent phase of the parasitosis, which allows the survival of the parasite inside cysts. Cysts can form in all tissues; yet, there is a preference for muscular and nervous tissues (neurons, astrocytes) and retinal cells. The disease is latent but can be activated after the rupture of a cyst. Bradyzoites then transform into infecting tachyzoites.

Rabbits get contaminated by eating food contaminated by cat feces that contain *Toxoplasma gondii* oocysts.

### Clinical manifestations in rabbits

Toxoplasmosis exists in different forms in rabbits: latent infection or progressive chronic or latent disease.



**Figure 5:** It is important to wash towels and pet beds regularly at high temperature to kill *Toxoplasma* oocysts. (Photos courtesy of Teresa Jarrett et Elise Church)

***Latent toxoplasma infection:*** Healthy and immunocompetent adult rabbits are seropositive for toxoplasmosis but remain asymptomatic during longer periods of time. The acquired immunity protects rabbits during their whole life. Cysts containing bradyzoites remain present in the tissues of the central nervous system. From time to time, cysts can rupture. The defense mechanisms of the immune system and the anti-toxoplasma antibodies enable control and limit the infections locally, hindering the spreading of bradyzoites throughout the body and the destruction of surrounding cells. The infection remains asymptomatic. During a necropsy, proliferation of supporting tissue of the central nervous system (gliosis) as well as granulomatous



encephalitis with perivascular cuffs or non-suppurated meningitis has been observed in rabbits suffering from this latent form of toxoplasmosis.

Chronic toxoplasma infection: it is mainly older rabbits that suffer from this form of infection. After a primary infection, cysts are formed in the muscular and nervous tissues of the animal. A reviviscence of the infection is possible after a period of stress or a disease accompanied by depression of the immune system. After the rupture of a cyst, freed bradyzoites start to multiply and to invade surrounding cells, leading to tissue damage. Rabbits suffering from this form of the disease become anorexic, lose weight and get an emaciated appearance. The illness is progressive and leads to a loss of coordination of movements (ataxia) and

paralysis of the posterior limbs (Figure 6). Fluid accumulation (edema) and necrotic foci are observed in different organs. Histopathology studies of tissues sampled from rabbits that died from chronic toxoplasmosis (spleen, liver and central nervous system) show marked hyperplasia of the reticulo-endothelial system.

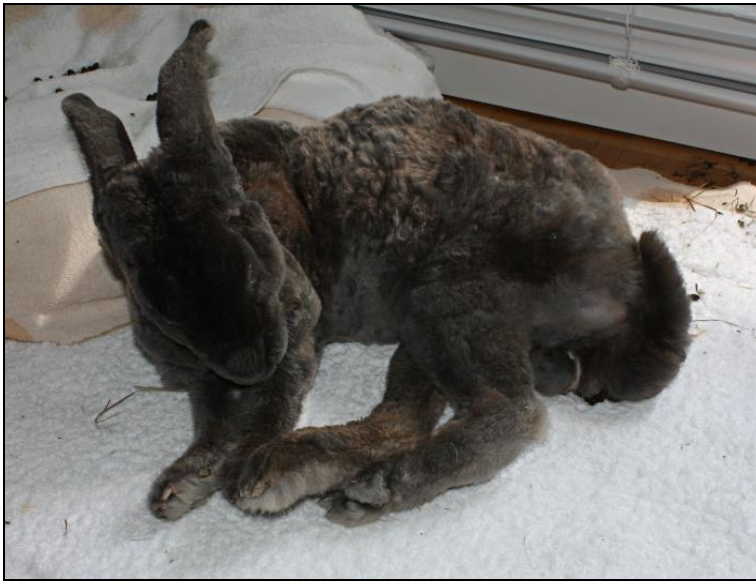The chronic form is rarely fatal to rabbits. Most will recover until the next reviviscence of the parasite. Clinical signs are similar to those of encephalitozoonosis. It is thus important to differentiate between the 2 diseases in order to start the correct treatment.

Acute toxoplasma infection: This form affects mostly younger rabbits and leads to death after 2 to 8 days post-infection. The first signs of the acute infection include a sudden lethargy with decreased appetite



**Figure 6:** Toxoplasmosis and encephalitozoonosis present similar clinical signs in rabbits: weight loss in spite of a good appetite and paralysis of the hind limbs.





**Figure 7** : Rabbit suffering from an epilepsy-like attack.

and pyrexia (over 41°C / 105.8°F). Rabbits refuse to drink and get dehydrated. Breathing rate is rapid (tachypnea). Eyes and nose may have a sero-purulent discharge. These rabbits will develop tremor of muscles and shaking of the head. Rarely, the head is tilted to one side, but this is not characteristic of the infection. Voiding of urine may be painful (dysuria).

Few days after the beginning of the disease, paresis or paralysis of hind limbs may develop and spread to the front limbs (tetraplegia). During the terminal phase of the disease, the rabbit suffers from convulsions and epileptic-like attacks, followed by death (Figure 7).

During necropsy, lesions and tissue necrosis are observed in various abdominal organs. There are fusiform necrotic foci in the heart. Edema and white or yellowish multifocal foci are present in the lungs. One French lop rabbit had spotted and dark colored lungs. White or yellow foci are also observed in the liver and spleen. Hepatomegaly and splenomegaly may lead to a major enlargement of these organs.

**Diagnostic**

Diagnostic of toxoplasmosis is based mainly of clinical signs of the sick rabbit. In order to differentiate this parasitosis from that caused by *Encephalitozoon cuniculi*, a serologic test is necessary in order to identify the presence of anti-toxoplasma antibodies (Almeria et al., 2004 ;

Figuro-Castillo et al., 2006 ; Zhou et al., 2013). A blood biochemistry panel may show an elevated level of creatinine, but this is not characteristic of the disease. This elevation may be the result of dehydration or stress.

Rabbit toxoplasmosis should also be differentiated from a head trauma.

## Treatment

The treatment of toxoplasmosis in rabbit is efficacious only during the tachyzoite stage – the infectious proliferative form of the parasite. Bradyzoites are not affected by the treatment as cysts offer them protection against their environment and isolate them from the blood circulation. Recurrence of the disease is possible after rupture of a cyst.

The treatment is similar to that administered to cats and includes:

- Sulfadoxine-trimethoprim antibiotic, 30-40 mg/kg, bid, PO,
- Pyrimethamine, 0.25-0.50 mg/kg, bid, PO, during 2 weeks.
- Folic acid, 3-5 mg, once a day to twice a week.

This treatment may lead to bone marrow suppression. It is thus advisable to do a regular blood panel if the treatment extends beyond 2 weeks.

Doxycycline alone or combined with other antibiotics such as azithromycin has successfully treated cerebral toxoplasmosis in other animals. Clindamycin should never be administered to rabbits; it causes severe dysbiosis of the bacterial intestinal flora and death of the rabbit.

Survival rate is very low and prognosis is poor due to the sudden and fast development of the parasitosis.

## Acknowledgments

Huge thanks to Norman Bowdler (UK), Denise Devoto (USA), Piper Provost (USA), Aveleira

Hayzel Sllhocin (USA), Teresa Jarrett (USA) et Elise Church (USA) for their pictures of rabbits with cats and to Janet Geren (USA) for her precious help in getting these pictures. Many thanks also to Bonnie Salt (USA).

This article is written in honor of Flora who fought her disease with a high spirit and courage.



## References

- Almería S, Calvete C, Pagés A, Gauss C, Dubey JP. Factors affecting the seroprevalence of *Toxoplasma gondii* infection in wild rabbits (*Oryctolagus cuniculus*) from Spain. *Vet Parasitol.* 2004;123(3-4):265-70.
- Beverley JK. Toxoplasmosis in animals. *Vet Rec.* 1976 Aug 14;99(7):123-7.
- Cox JC, Edmonds JW, Shepherd RC. Toxoplasmosis and the wild rabbit *Oryctolagus cuniculus* in Victoria, Australia with suggested mechanisms for dissemination of oocysts. *J Hyg (Lond).* 1981;87(2):331-7.
- Dubey JP, Passos LM, Rajendran C, Ferreira LR, Gennari SM, Su C. Isolation of viable *Toxoplasma gondii* from feral guinea fowl (*Numida meleagris*) and domestic rabbits (*Oryctolagus cuniculus*) from Brazil. *J Parasitol.* 2011;97(5):842-5.
- Figuroa-Castillo JA, Duarte-Rosas V, Juárez-Acevedo M, Luna-Pastén H, Correa D. Prevalence of *Toxoplasma gondii* antibodies in rabbits (*Oryctolagus cuniculus*) from Mexico. *J Parasitol.* 2006 Apr;92(2):394-5.
- Gustafsson K, Uggla A, Järplid B. *Toxoplasma gondii* infection in the mountain hare (*Lepus timidus*) and domestic rabbit (*Oryctolagus cuniculus*). I. Pathology. *J Comp Pathol.* 1997a;117(4):351-60.
- Gustafsson K, Watrang E, Fossum C, Heegaard PM, Lind P, Uggla A. *Toxoplasma gondii* infection in the mountain hare (*Lepus timidus*) and domestic rabbit (*Oryctolagus cuniculus*). II. Early immune reactions. *J Comp Pathol.* 1997b;117(4):361-9.
- Ishikawa T, Nishino H, Ohara M, Shimosato T,

- Nanba K. The identification of a rabbit-transmitted cervical toxoplasmosis mimicking malignant lymphoma. *Am J Clin Pathol.* 1990 Jul;94(1):107-10.
- Kapperud G. Survey for toxoplasmosis in wild and domestic animals from Norway and Sweden. *J Wildl Dis.* 1978 Apr;14(2):157-62.
- Lainson R. The demonstration of *Toxoplasma* in animals, with particular reference to members of the Mustelidae. *Trans R Soc Trop Med Hyg.* 1957;51(2):111-8.
- Neumayerová H, Juránková J, Jeklová E, Kudláčková H, Faldyna M, Kovařík K, Jánová E, Koudela B. Seroprevalence of *Toxoplasma gondii* and *Encephalitozoon cuniculi* in rabbits from different farming systems. *Vet Parasitol.* 2014;204(3-4):184-90.
- Sroka J, Zwolinski J, Dutkiewicz J, Tós-Luty S, Latuszyńska J. Toxoplasmosis in rabbits confirmed by strain isolation: a potential risk of infection among agricultural workers. *Ann Agric Environ Med.* 2003;10(1):125-8.
- Zhou Y, Zhang H, Cao J, Gong H, Zhou J. Isolation and genotyping of *Toxoplasma gondii* from domestic rabbits in China to reveal the prevalence of type III strains. *Vet Parasitol.* 2013;193(1-3):270-6.