



Unilateral agenesis of the fibula and tibia and bilateral congenital apodia in a Rex rabbit

Janet E. Geren, Esther van Praag

Developmental arrest of a limb is very rare in rabbits. In a mild form, fingers are shortened while a severe defect is characterized by the absence of the distal ends of a limb (acheiropodia).

Limb malformations belong to a complex group of disorders that are part of polymalformative syndromes (Figures 1, 2). Their terminology is difficult and specific. Etiology of these defects is wide-ranging:

- Embryofetopathy, anomalies affecting the embryo and, later, the fetus.
- Malformation due to a chromosomal anomaly.

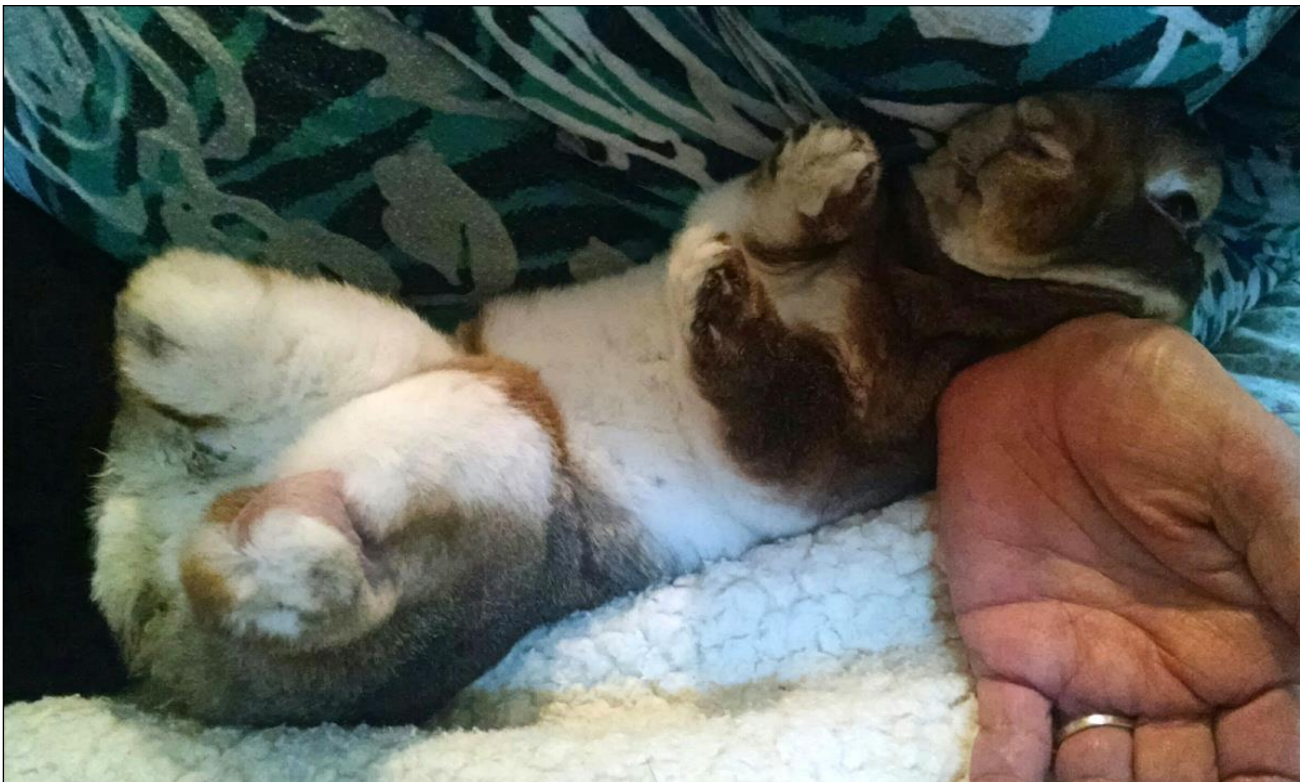


Figure 1: Micah is a 4 year old non-castrated male rabbit that present a lack of digits and feet on his lower limbs, a shortening of the fibula and tibia in his right lower limb, a loss of the distal portions of the ear pinna and a nearly missing tail.

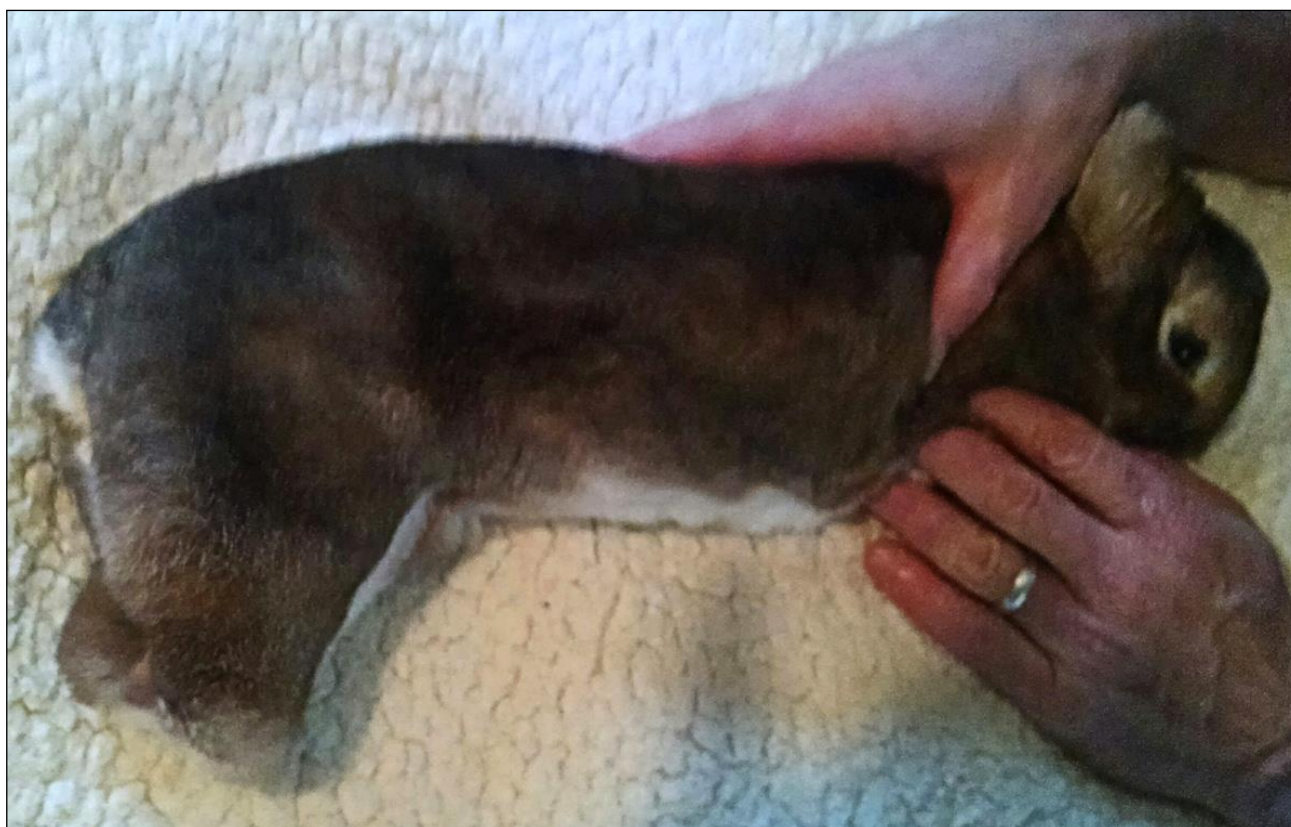

Figure 2 : Micah, un lapin mâle non castré de race Rex avec une absence congénitale des parties distales aux membres inférieurs, une hémimélie du péroné et tibia droit.

- Genic disease due to the presence of one or more defective genes.
- Polymalformative syndrome without genetic cause.

There are several types of defects. The transverse deficiency is characterized by a developmental arrest of the terminal (distal) portion of a limb (terminal aplasia). The deficit may vary in severity:

- Abnormal or incomplete development of the fingers. It may be accompanied by syndactyly: the finger skin is joined together or the finger bones are fused.
- Absence of a hand or a foot.
- Lack of a hand or a foot, accompanied by the absence of the forearm or lower limb.
- Absence of limb(s).

Sporadic causes

Limb defects are often sporadic. They are caused by vascular accidents during the limb development in the fetus. Amelia affects usually one limb only; it is unilateral and isolated.

In rabbits, more or less severe sporadic limb malformations are uncommon. Their causes are not well understood. Most cases are isolated. There is no family history and the anomaly is no more observed in the offspring.

Non-sporadic causes

Non-sporadic malformations are rare (Figure 3). X-ray studies have enabled veterinarians and radiologists to visualize when there is a partial or complete lack of bone structures (Greene et Saxton, 1939). There is a high degree of variability (Figures 3, 4). This diversity of clinical types renders

analysis difficult. Therefore deficits have been classified into 3 types (Greene et Saxton, 1939). There is a high degree of variability (Figures 3, 4). This diversity of clinical types renders analysis difficult. Therefore deficits have been classified into 3 types (Greene et Saxton, 1939):

- Type 1: mild brachydactylia with shortened or absent fingers.
- Type 2: acheiropodia with changes in the bone structure of the metacarpus and tarsus. The lack of hands and feet (aplasia of carpal bones, metacarpus, tarsus and

metatarsus and digits) on one, several or all limbs have usually a genetic origin. The absence of feet, rather than that of hands is often related to a syndrome transmitted according to a recessive autosomic inheritance mode. Acheiropodia may be accompanied by the absence of a forearm or the lower part of the hind limb.

- Type 3: tetraamelia with changes of the bone structures of the wrist and ankles. The full lack of all 4 limbs is linked to an autosomic recessive gene. Further skeletal anomalies are sometimes present: aplasia

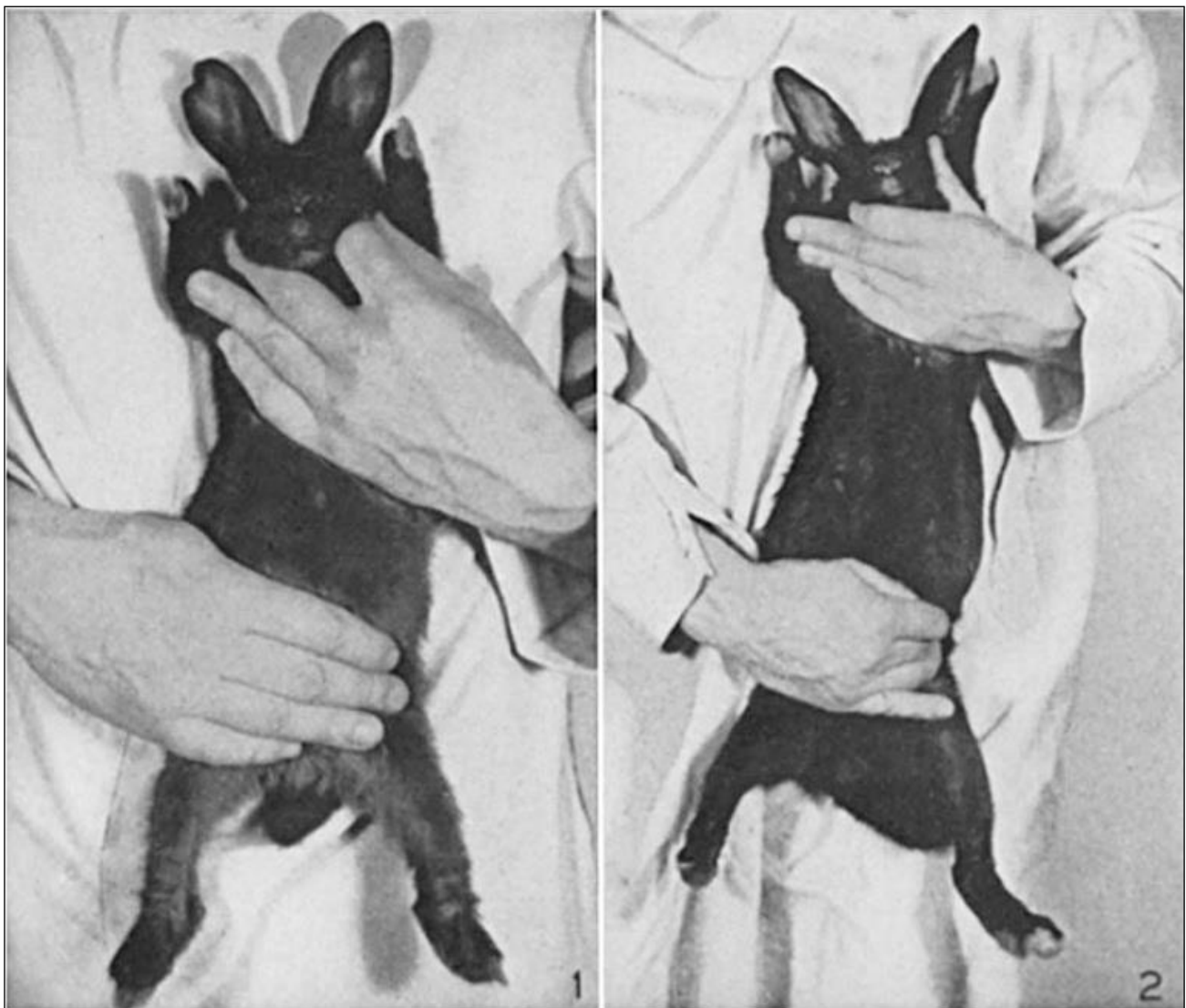


Figure 3: Young rabbits presenting an almost complete absence of digits on all limbs (1, 2). In one of the rabbits, the malformation of digits is accompanied by the loss of the distal portion of the right ear pinna (1). Photos taken from Greene et Saxton, 1938.

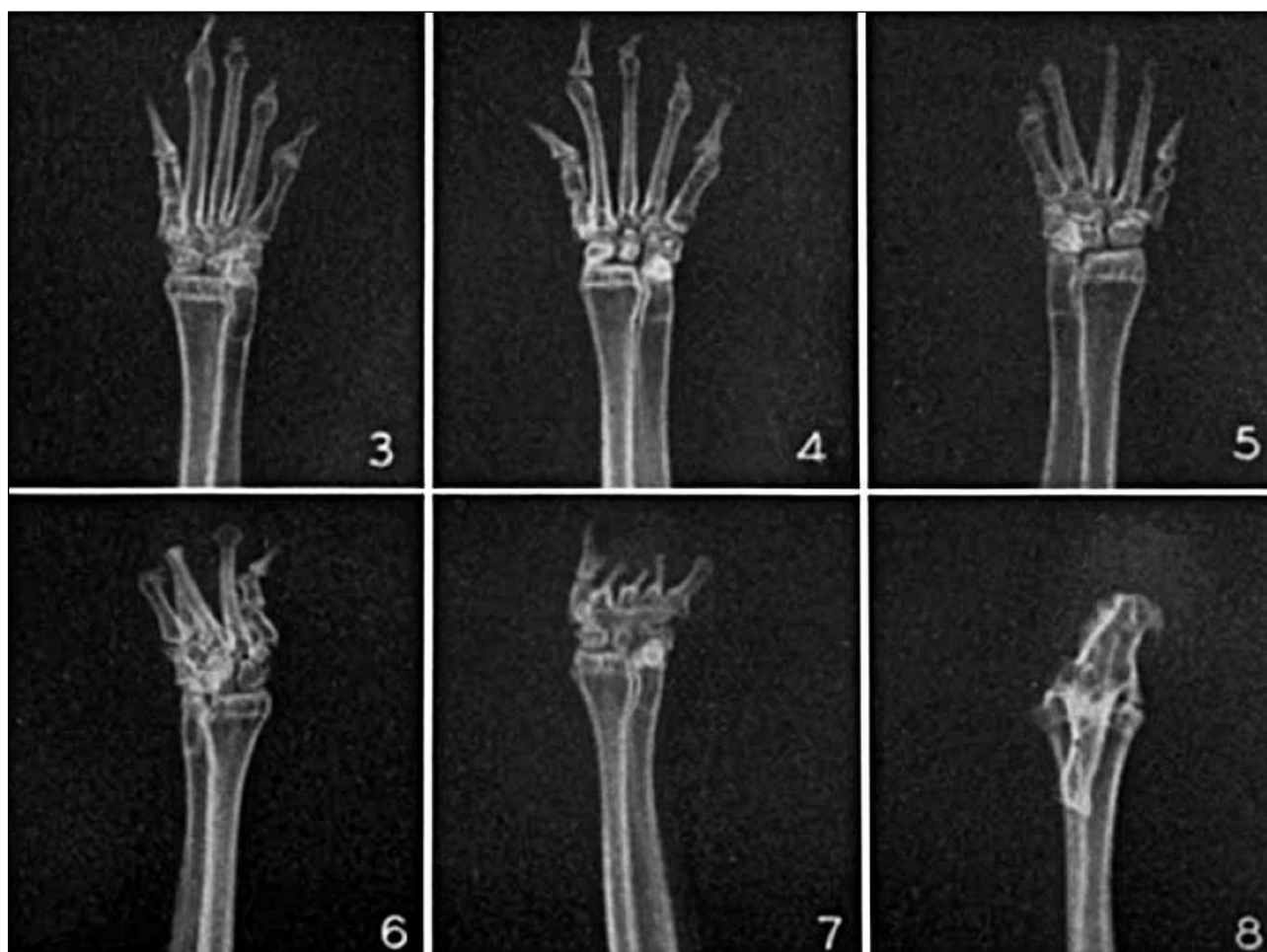


Figure 4: X-rays of the front limbs of bachydacteleous rabbits: loss of one or several digits (3) and metatarsal bones (4, 5, 6, 7). The limb in Figure 8 has only the wrist bone. Photos taken from Greene et Saxton, 1938.

of ribs, vertebra, of the pelvic bone, modifications of the face, and of the cardiovascular and urogenital systems.

The most significant modifications of the skeleton are observed when the bones of the metacarpus or the metatarsus are absent. When the foot is absent (acheiropodia), bones of the terminal parts of the front or hind limbs present only few changes, for example a decrease of their diameter and their length (Figure 4).

Bilateral forms have a genetic origin, with one or more anomalies on one or several chromosomes. When lower limbs are affected, the malformation is often related to other pathologies.

A hereditary character is sometimes observed and the anomaly is passed from one generation to the next. The anomaly can be unilateral or bilateral.

Some cases of brachydactylous rabbits have been described during the 20th century (Greene and Saxton, 1939; Inman, 1941; Jost and al., 1969; Ehrensperger and al., 1981).

This congenital development defect is caused by the *br* "brachydactylia" autosomal recessive gene. Homozygous *br/br* rabbits present a shortening or a loss of digits and even of the carpal or tarsal bones, respectively of hands and feet (Figure 1) on

one or several limbs. Front limbs are more often affected than the hind limbs.

Other developmental defects of the skeleton can accompany the malformations of the limbs, but are rare or non-existent in rabbits.

Rabbits with the *br/br* genotype may also suffer from ear deformations. Indeed, during the development of the embryo, buds of the limbs and those of the ears develop at the same moment (Greene and Saxton, 1939). The modifications observed on the ear pinna are varied and frequent (Figure 5). They are located on the free edges of the ears (Greene et Saxton, 1939):

- Loss of the distal portion;

- Blunt end;
- Notched edges of the ear pinna;
- Narrow ear pinna.

The degree to which ears are affected is individual and varies from one rabbit to another. Length of the ear may be reduced by as much as a third of the length in the most severe cases. Generally, only one ear is affected, more rarely both, in an asymmetric way (Greene and Saxton, 1939). Malformations of the inner ear are also present in 25% of *br/br* rabbits.

Adult *br/br* rabbits suffering from brachydactylia have, in addition, reduced reproductive and maternal instincts: reduced fertility rates or sterility, reduced size of litters and limited to non-existent maternal care.



Figure 5: Bilateral loss of the distal portion of the ear pinna.

Development of *br/br* embryo

Starting on the 12th day of fetal development, degenerative changes are observed in the blood vessels such as inflammation of the endothelium in the limbs. It leads to a widening of the blood vessels and their rupture between the 18th and the 20th day of gestation. Hemorrhages that result from the vessel rupture will cause necrosis of mesenchyme tissue (accumulation of cells that develop into connective tissue, muscle, cartilage, nerves) before the 25th day of gestation (Greene and Saxton, 1939). Growth of loose scar connective tissue around the bone buds during the critical period of embryonic limb leads to the disruption of the osseous centers of the fingers and sometimes of the metacarpi or the metatarsi and the arrest of their growth. The epithelium covering these regions is not affected despite the absence of blood circulation and even tends to grow well.

Studies of the blood composition in *br/br* fetuses have highlighted various anomalies (Ehrensperger et al., 1981; Petter et al., 1977). The *br/br* fetuses have an excess of red blood cells in the blood (polycythemia). A large number of red blood cells have an abnormally large size (macrocytosis) due to an anomaly during the process of erythrocytes production (erythropoiesis). Blood clots may form, causing hemorrhages at the terminal end of limbs. It results in post-natal amputations. Finally, the liver has a low level of hematopoietic cells on the 15th day of gestation. Hepatic tissue returns to normal at day 17.

Pregnant females that received folic acid and vitamin B₁₂ supplements or that have been placed in an environment rich in oxygen gave birth to normal new-born, without congenital limb anomalies (Boucher-Ehrensperger and Petter, 1984; Petter et al., 1977).

Longitudinal fibular hemimelia

Congenital anomalies of the fibula include the fibular hemimelia, which is the partial or total absence of the fibula bone in the lower part of the hind limb. In most cases, a single hind limb is affected and the right limb is more often affected than the left one.

This defect is usually sporadic. It is observed more often in males than females. In man, it is transmitted via an autosomal dominant pattern of inheritance and an incomplete penetrance was observed in only a few families.

The etiology of fibular hemimelia is not well understood. As for brachydactylia, degeneration of the blood vessels during the embryonic limb development is suspected. Another possible vascular cause may be the absence of the anterior tibial artery. Other factors include a trauma, a viral infection or administration of a drug with teratogenic effects.

Fibular hemimelia has been classified into different types depending on the severity of the fault:

- Type I with partial absence of the fibula,
- Type II with the total absence of the fibula.

The femur may be shortened or curved.

Hemimelia can be a single deformation or it may be associated with other malformations:

- Osseous origin, like brachydactyly with a total absence of digits and feet.
- Extra-osseous origin, like ocular, renal or cardiac abnormalities.

It seems that no case of natural fibular hemimelia associated with a shortening of the tibia has been described in the rabbit to this day.

Nutritional deficiencies

Malformations of limbs can be caused by nutrient deficiencies (pantothenic acid, vitamins) in female rats during gestation. They cause vascular lesions at the extremity of limbs of the fetus. It results in more or less important alterations of the skeleton of limbs such as the absence of hand or feet. Hind limbs are more affected than the front limbs.

In rats, deficiency in pantothenic acid, furthermore, induces other defects such as malformations of the jaw, anophthalmia, microphthalmia, exencephalia or pseudoencephalia (Lefèbvres, 1951, Giroud et al., 1955).

Neonatal mutilations

The development of the maternal instinct in wild and domestic rabbits is a complex process that is controlled by hormones. This includes the building of a nest by the gathering and accumulation of straw, hay and hair torn from the body, as well as the inhibition of cannibalistic behavior with mutilation and nibbling of protruding parts of the body of the newborn or the body itself (Figure 6).

A doe that has just given birth to a litter is very sensitive to her environment. Stress caused by the presence of rodents or predators as well as her survival instinct can lead her to mutilate or eat her kits. Lack of food (insufficient amount, low in calories or deficient in minerals or vitamin B) and water are other causes of mutilation and/or cannibalism.

After giving birth, the doe eats the placenta attached to the newborn. When cleaning her newborn, she may accidentally bite off the ears, tail or limbs of her kit and maim it (Figure 6). In addition, a female doe can have an extreme maternal instinct and may injure her newborn by licking it excessively.

The extent of the mutilations and the number of kits in a litter that suffer from the behavior of a lactating doe vary: one to several or all rabbits may be affected.

Iatrogenic medication causes

Medication like thalidomide, valproate, hydantoins or viral diseases can lead to limb malformations, with abnormally short limbs or absent limbs (phocomelia). Usually all 4 limbs are affected.

Micah, a special dwarf Rex rabbit

Brachydactyly is usually found in a rabbit lineage. Malformations affecting parents are observed with varying degrees of severity in the offspring. Yet, this malformation is rare in the general rabbit population.

A pet rabbit with missing fingers or without feet can have a good quality of life and a good health. Malformations do barely interfere with his movements, when moving around. Special attention must, however, be brought to the affected limbs. Indeed, the pressure of body weight is not spread over the entire surface of the hands or feet, but on a small surface only. These rabbits are more susceptible to pododermatitis. This is also the case of Micah, who is a 4 years old Rex dwarf rabbit (Figures 1, 2, 5). This male is not neutered and weighs 1.7 kilos. This rabbit is the only one in his litter to present a congenital bilateral absence of feet, shortened ear pinnae and a narrow ear canal when compared with a normal rabbit and a very small tail. He leads a normal pet rabbit life and is active despite the absence of both rear feet and digits.

Physical examination of Micah

The physical examination of this rabbit confirms that he has no anomalies on the head, thorax or abdomen as well as the

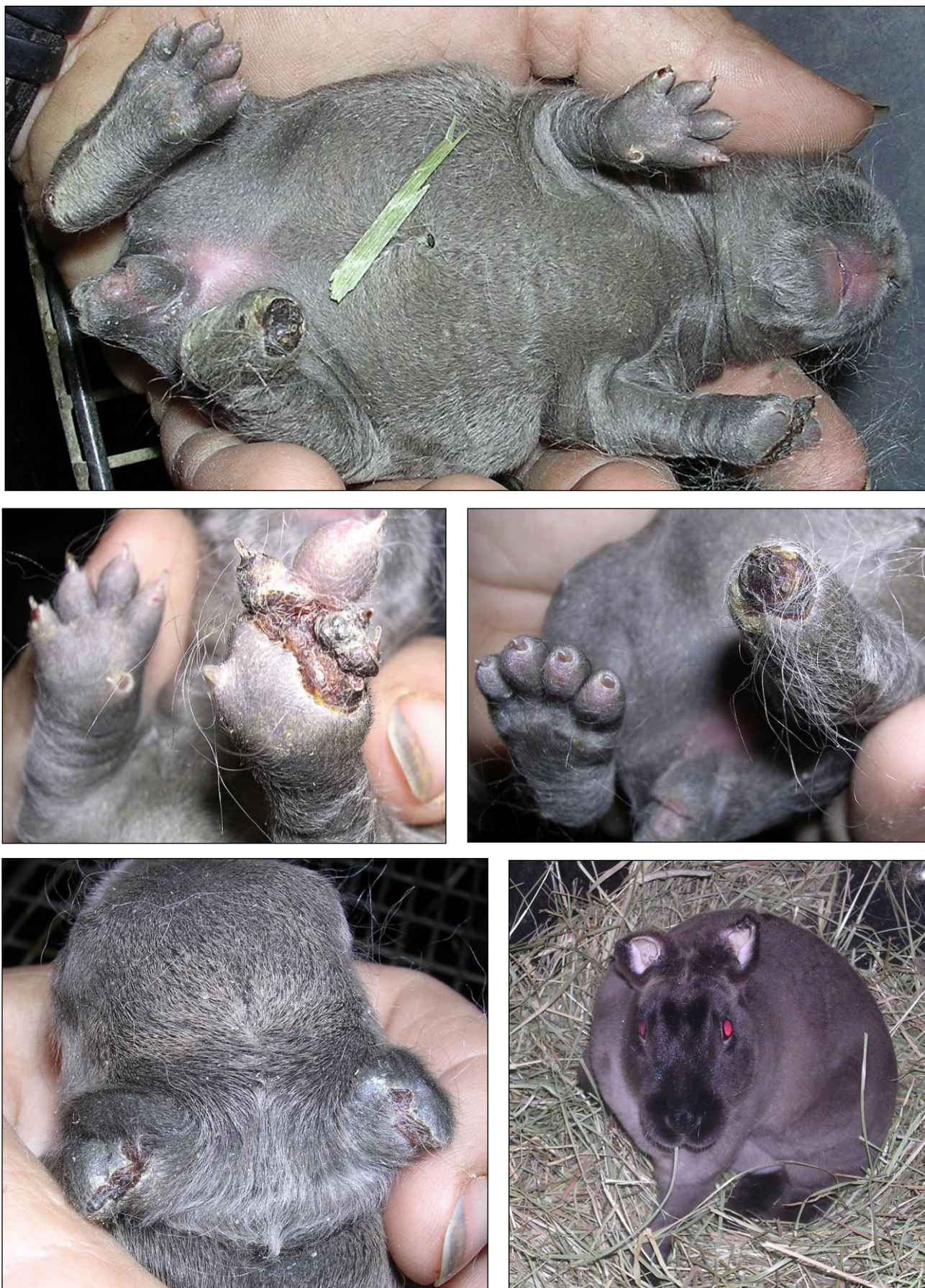

Figure 6: Newborn that has been severely mutilated by the doe, and details of the ears, the front limb and the hind limb. The female newborn survived her wounds and has become an adult rabbit. Photos : Pamela Alley.



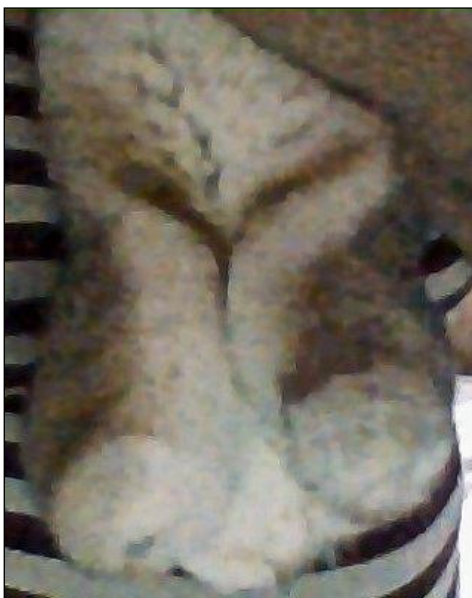Figure 7: Micah, a rabbit unlike any other with such a rabbit behavior.

front limbs. However, he has several anomalies and malformations too:

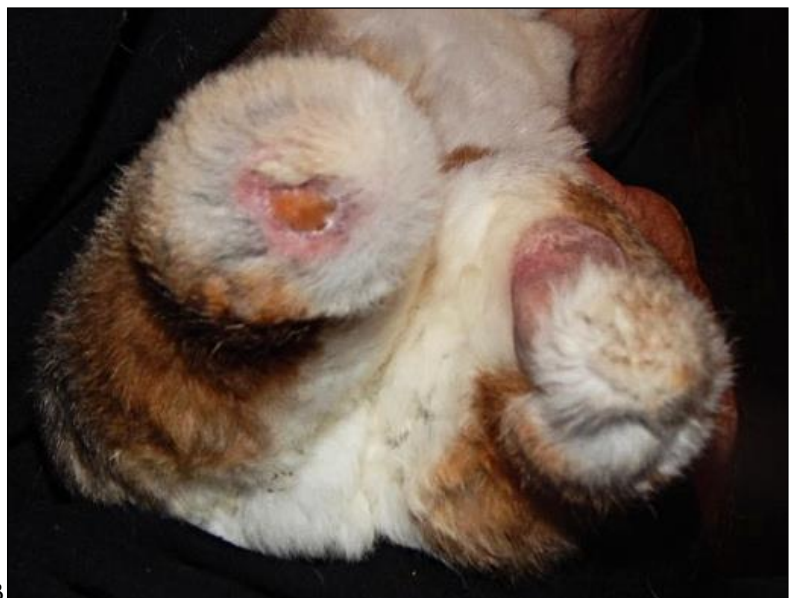- Ear pinnae with a reduced length and a

very narrow opening of the ear canal (Figures 5, 7, 9).

- Reduced to absent tail (Figure 10).



A



B

Figure 8: View on the bottom « feet » part of the hind limbs of Micah when he was young (A) and at the age of 4 years, with signs of pododermatitis (B).

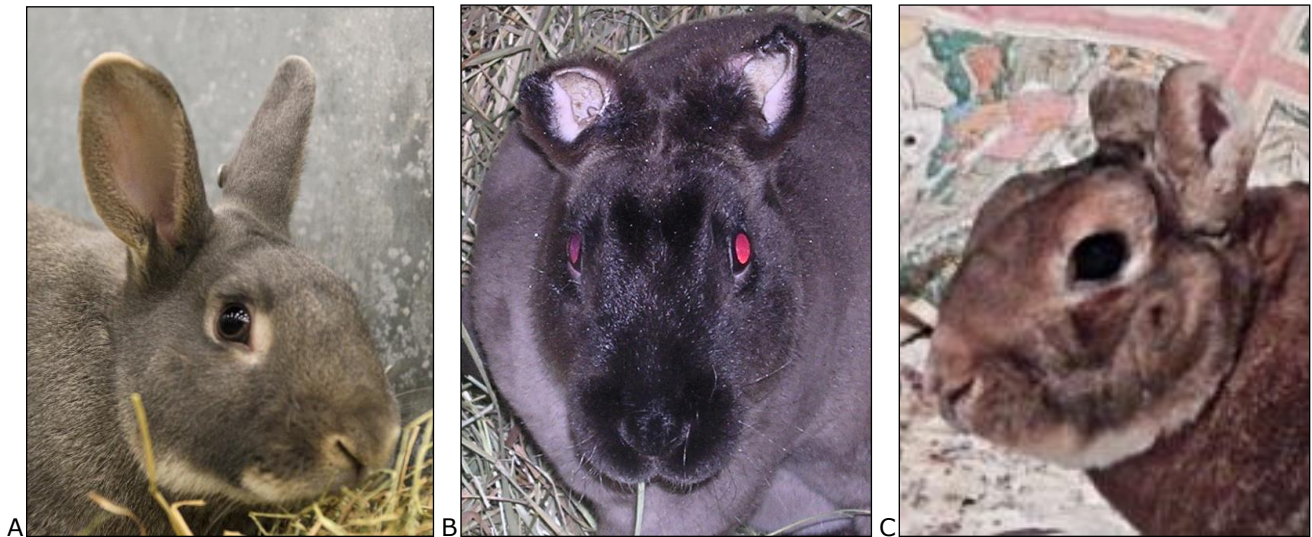


Figure 9: Comparing the structure of the ear pinna in a normal male dwarf rabbit (A), in a rabbit Rex whose ears were mutilated by the doe after birth (B) and those of Micah whose end is rounded and narrow and not angular as seen in mutilated rabbits (C).

- Absence of testis in the scrotum (cryptorchidism) (Figure 11).
- Total absence of feet on the hind limbs (Figures 1, 2, 5, 8, 10, 12).
- Shortened fibula and tibia bones in the right hind limb. Their length is reduced by roughly one third (Figure 12). The extremities of the hind limbs are covered

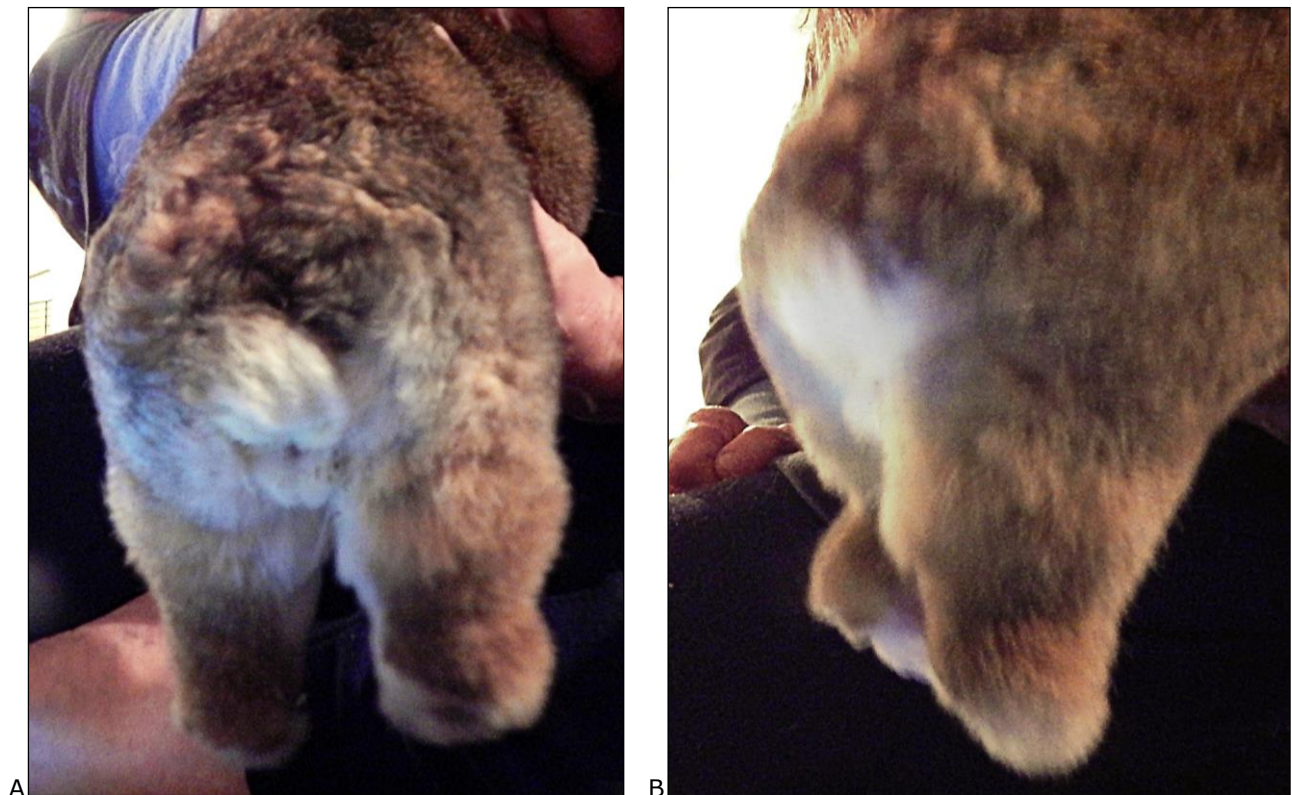


Figure 10: Much reduced to absent tail in Micah.

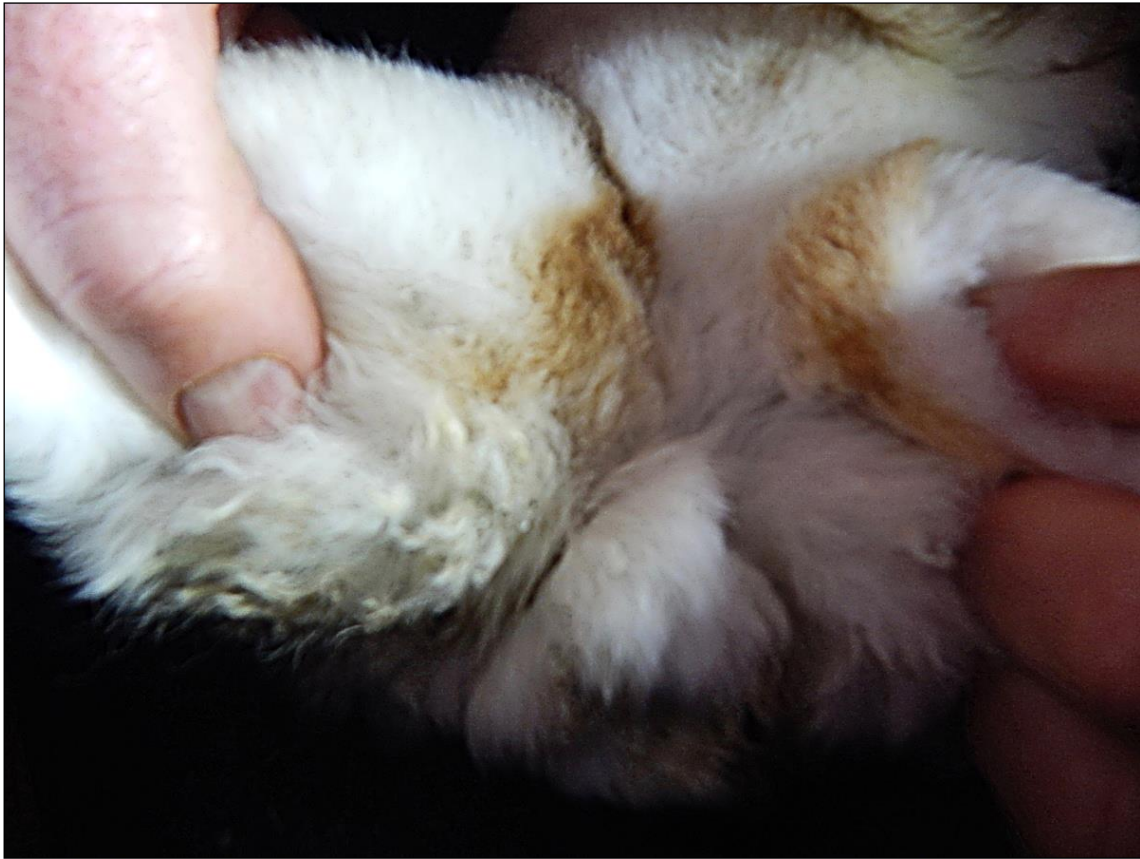

Figure 11: Micah is a cryptorchid male rabbit. His testis never descended into the scrotum. For this reason he could not be neutered.

with fur whose density is very similar to that found under the feet of normal rabbits. Only the surface is very small (Figure 8A). Pododermatitis developed in spite of all the good care given to this rabbit and moving on soft ground covered with artificial sheep skin (Figure 8B).

Radiography of the limbs

X-rays were taken of the front and hind limbs of Micah in order to clarify the cause of his limb malformations.

X-ray of the distal end of the front limbs show that the ulna and radius articulate with the carpal bones (Figure 13A, B). The 8 carpal bones are arranged in rows. The digits are long and slender. The metacarpal bones have different lengths. The bones of the 5 digits are formed by 14 bones, 2 in the first

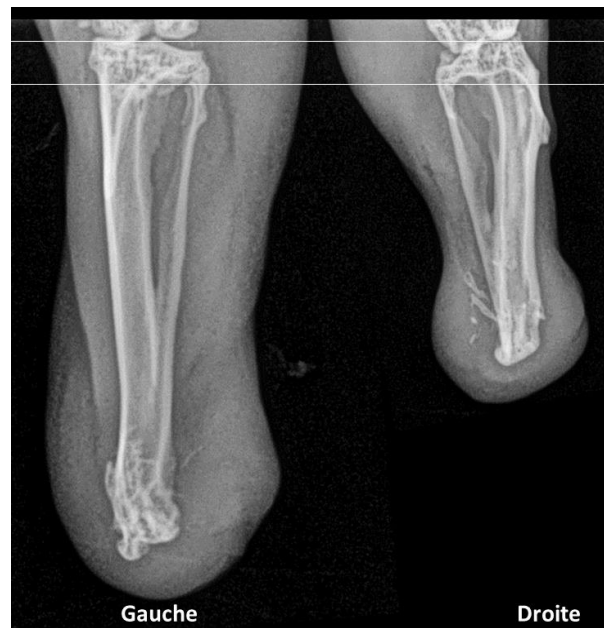

Figure 12: X-rays of the left (gauche) and right (droite) hind limbs showing a moderate hypoplasia of the fibula and the tibia in the right limb.

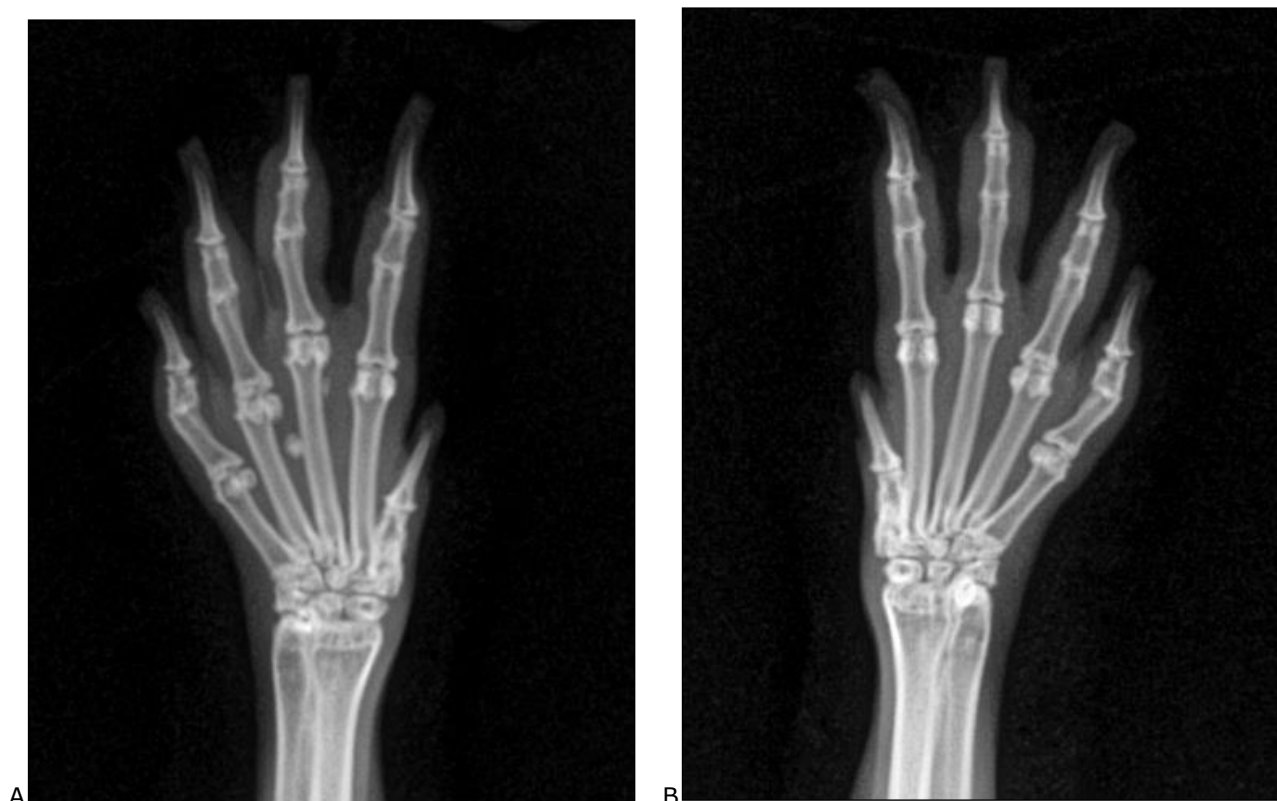

Figure 13: X-rays of Micah's right (A) and left (B) front paws. They do not present malformations in the bones of the fingers and the metacarpus.

finger and 3 in the 4 remaining fingers. The anatomy and morphology of the front limbs is thus characteristic of that of normal rabbits and does not present anomalies.

X-rays of the lower limbs show, however, severe modifications of the osseous anatomy, when compared to that of a normal rabbit (Figures 14, 15).

In the left lower hind limbs, the fibula and tibia bones have an approximately normal length. At the ankle, there is an osseous outgrowth at the distal end of the tibia. It may be a vestigial remnant of a tarsal bone that has fused to the tibia bone (Figure 14).

The lower right hind limb has shortened fibula and tibia bones; both bones seem to mix up at the distal (terminal) end (Figure 15). The tibia is curved backwards at its distal end. Such reduced length of both fibula and tibia is often accompanied by

apodia. This is the case here too: tarsal and digit bones are fully missing.

Conclusion

Development defects of the tibia and fibula and the absence of tarsal and digit bones are accompanied by malformations in different regions of the body. Some are associated to the *br/br* genotype (ears), while others are not (shortened to absent tail, cryptorchidism). All observed anomalies are very different from those observed in rabbits mutilated by the doe when she licked them to free them from the placenta. The anomalies observed in Micah thus appear rather to have a genetic and congenital origin.

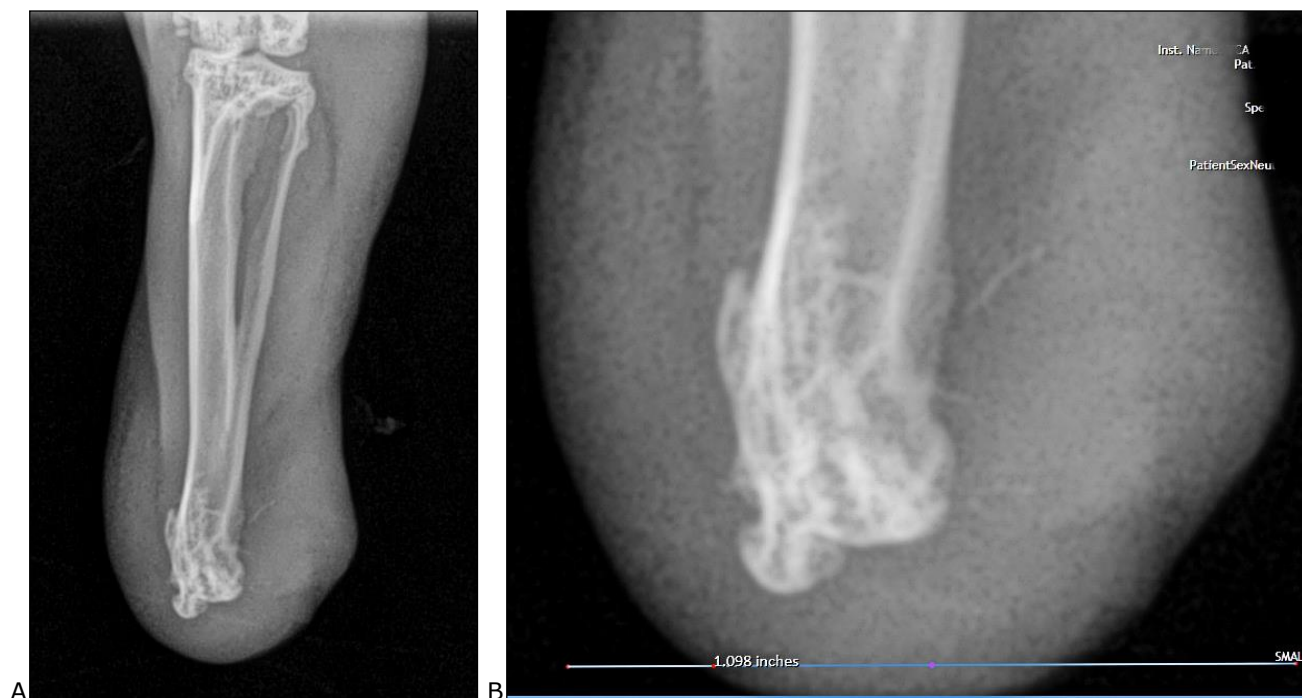

Figure 14: X-rays of the left hind limb of Micah (A) and detail of the terminal end (B). There seems to be a vestigial residue of the tarsal bone.

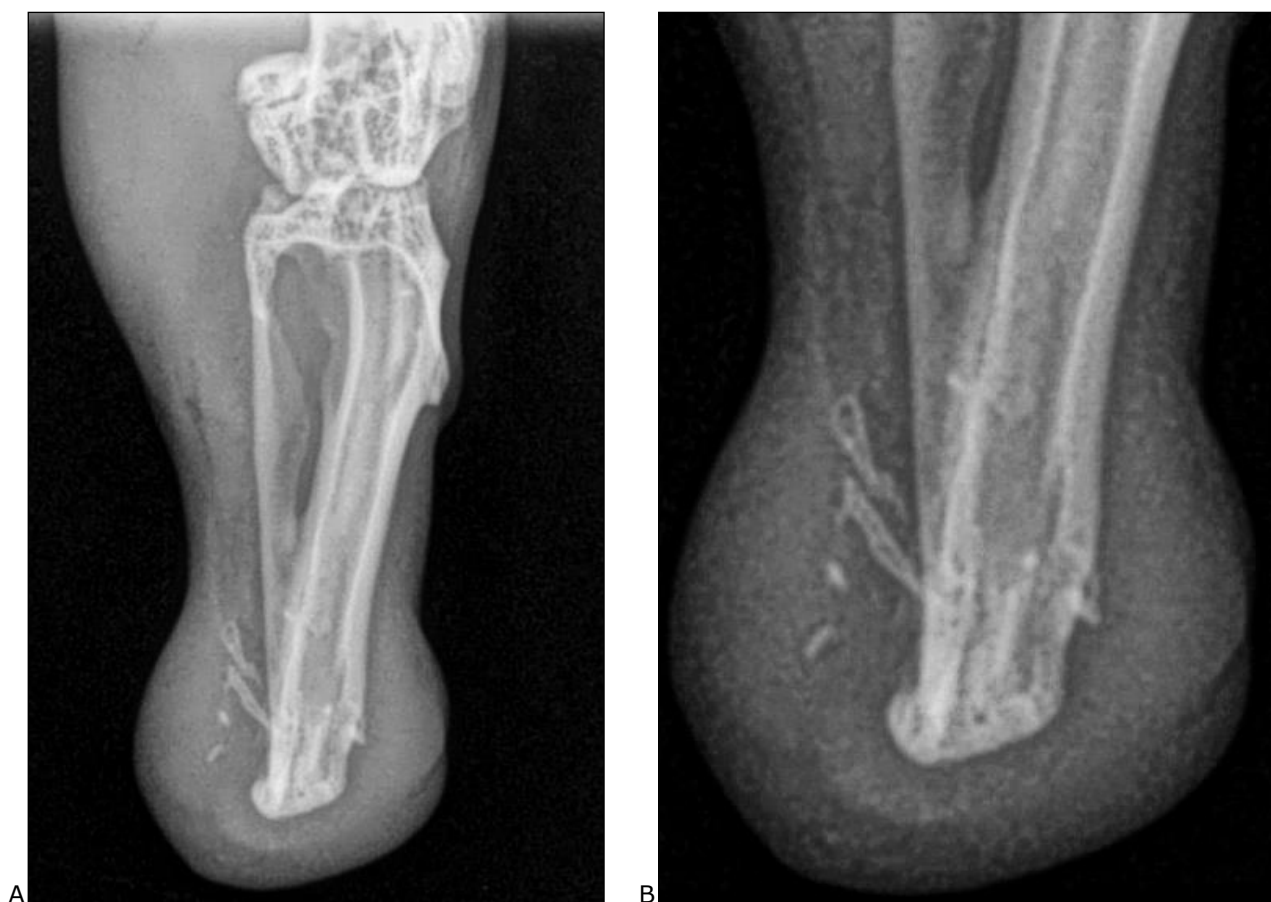

Figure 15: X-rays of the right hind limb of Micah (A) and detail of the terminal end with the curved tibia (B).

Acknowledgements

A huge big thanks to Larry Correia, DVM (VCA Asher Animal Hospital, Redding C, USA) for his kindness and collaboration for the x-rays taken from Micah, to Randy Geren (USA) and to Pamela Alley (USA) for the pictures of the mutilated newborn.

References

- Boucher-Ehrensperger M, Petter C. Prevention of thrombocytic defects in the br/br rabbit with folic acid and vitamin B12: analogy with the T.A.R. syndrome in humans. *Int J Vitam Nutr Res.* 1984;54(2-3):199-203.
- Ehrensperger M, Petter C, Keuky L. Foetal megakaryoblastic abnormality associated with congenital limb amputation in the br/br rabbit. *J Embryol Exp Morphol.* 1981;62:109-15.
- Giroud A, Lefebvres J, Prost H, Dupuis R. Malformations des membres dues à des lésions vasculaires chez le fœtus de rat déficient en acide pathoténique. *J. Embryol. Exp Morphol.* 1955;3:1-12.
- Greene HS, Saxton JA. Hereditar brachydactylia and allied abnormalities in the rabbit. *J Exp Med.* 1939;69(2):301-14.
- Inman OR. Embryology of hereditary brachydactyly in the rabbit. *Anat. Rec.* 1941;79,483-505.
- Lefebvres J. Rôle tératogène de la déficience en acide patothénique chez le rat. *Ann. Méd.* 1951;52:225-299.
- Petter C, Bourbon J, Maltier JP, Jost A. Primordial red cells and congenital amputation in rabbit fetuses bearing the br gene. *C R Acad Sci Hebd Seances Acad Sci D.* 1973 Sep 3;277(9):801-3.
- Petter C, Bourbon J, Maltier JP, Jost A. Simultaneous prevention of blood abnormalities and hereditary congenital amputations in a brachydactylous rabbit stock. *Teratology.* 1977;15(2):149-57.