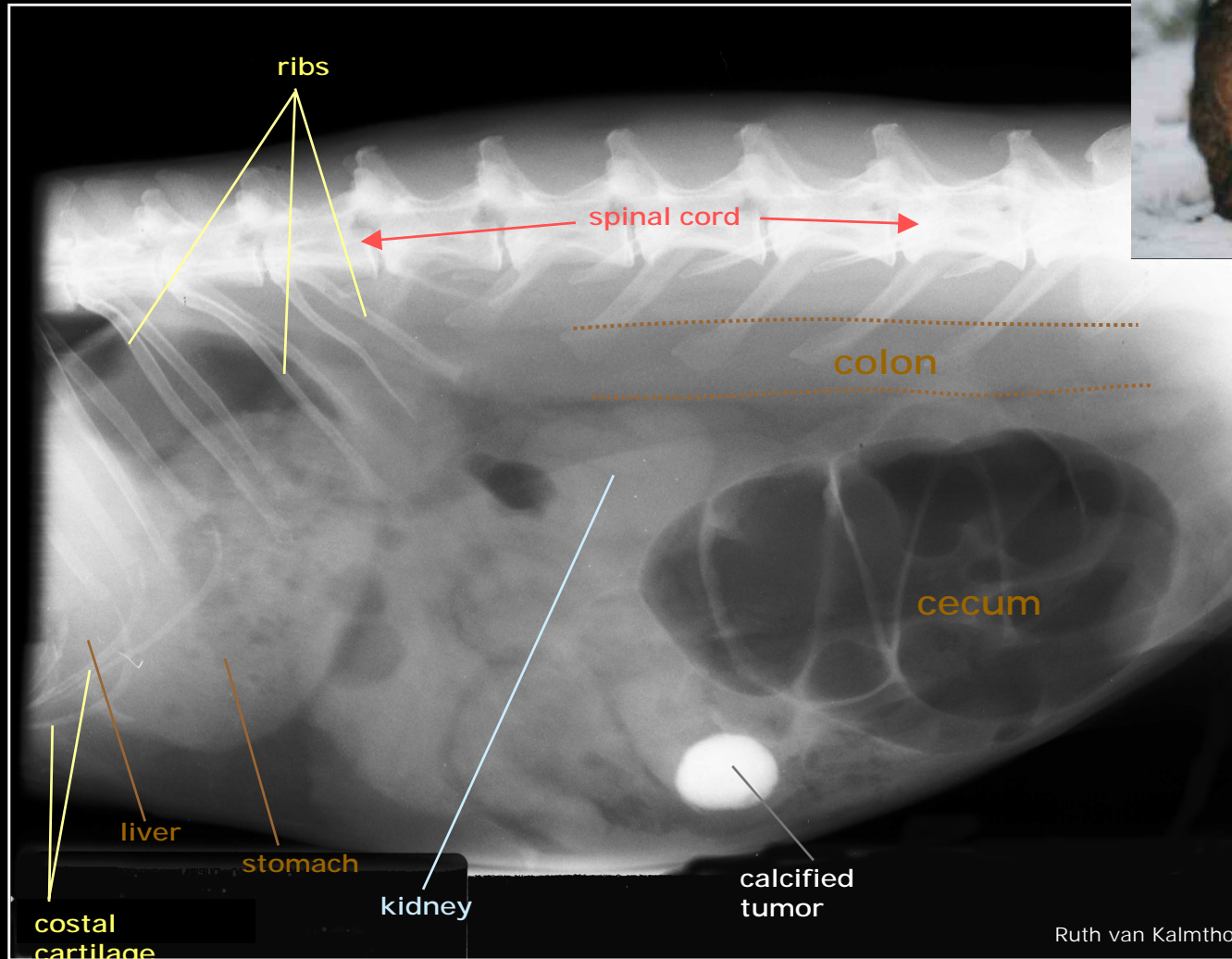




Laterolateral radiography of the viscera: neoplasia



Hazel



Ruth van Kalmthout