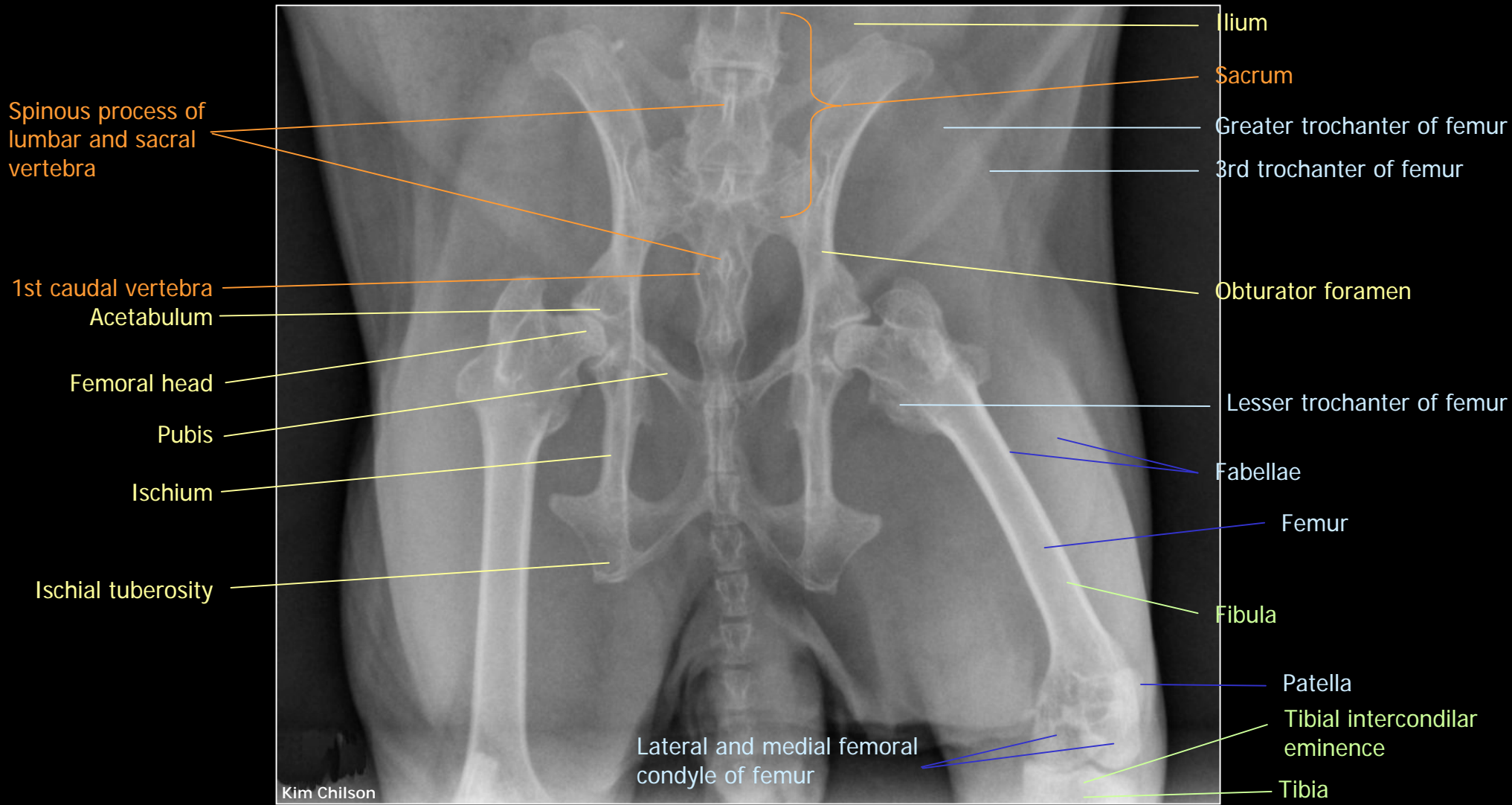




# Ventro-dorsal radiography of the rabbit pelvic region



The information on this page may not be reproduced, or republished on another webpage, website, or elsewhere.