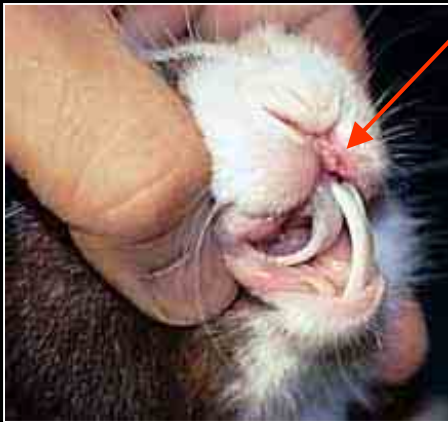



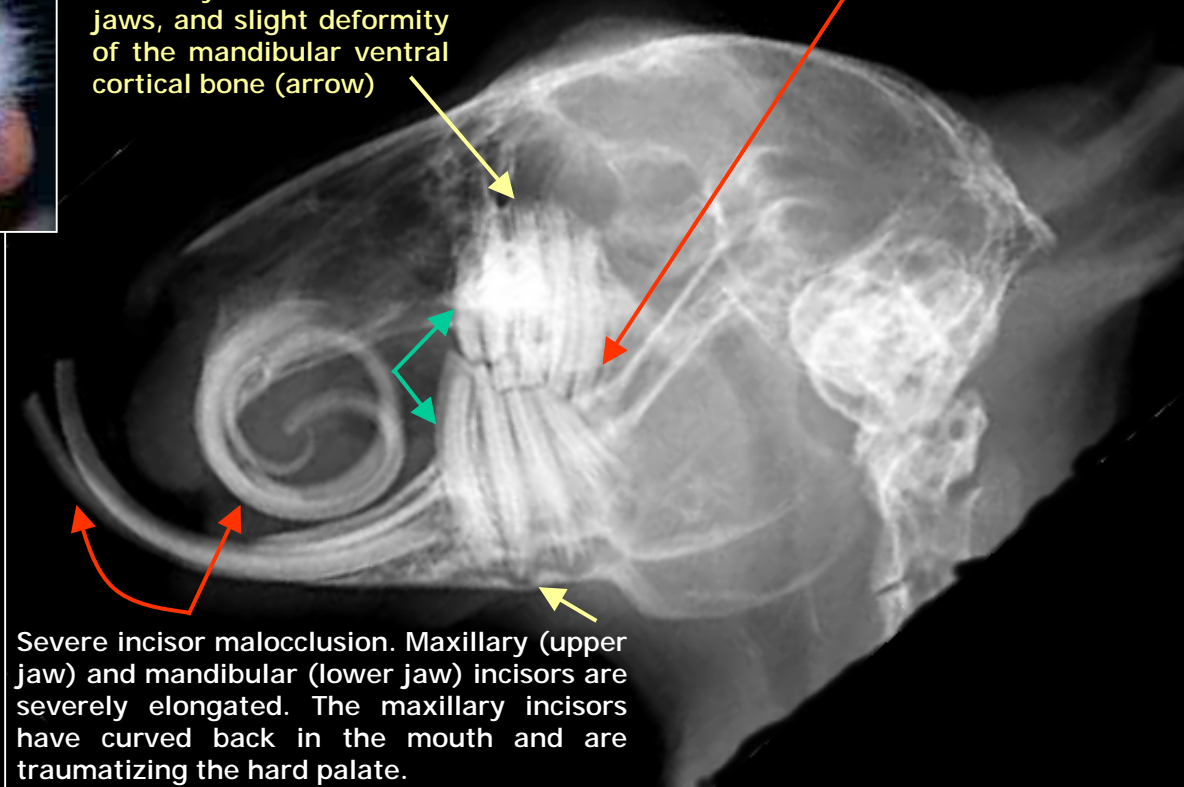
Radiography of a rabbit suffering from severe incisor and molar malocclusion



Lips traumatized by the elongated mandibular incisor

Root elongation on both maxillary and mandibular jaws, and slight deformity of the mandibular ventral cortical bone (arrow)

Excessive and irregular crown elongation, with height differences of a few millimeter, and curving of the first premolar (increased mesial convexity – green arrows)



Severe incisor malocclusion. Maxillary (upper jaw) and mandibular (lower jaw) incisors are severely elongated. The maxillary incisors have curved back in the mouth and are traumatizing the hard palate.

VEIN (Veterinary Exotic Information Network) System, Copyright © 2002 Shinkichi Tsuruno and Akira Yamanouchi