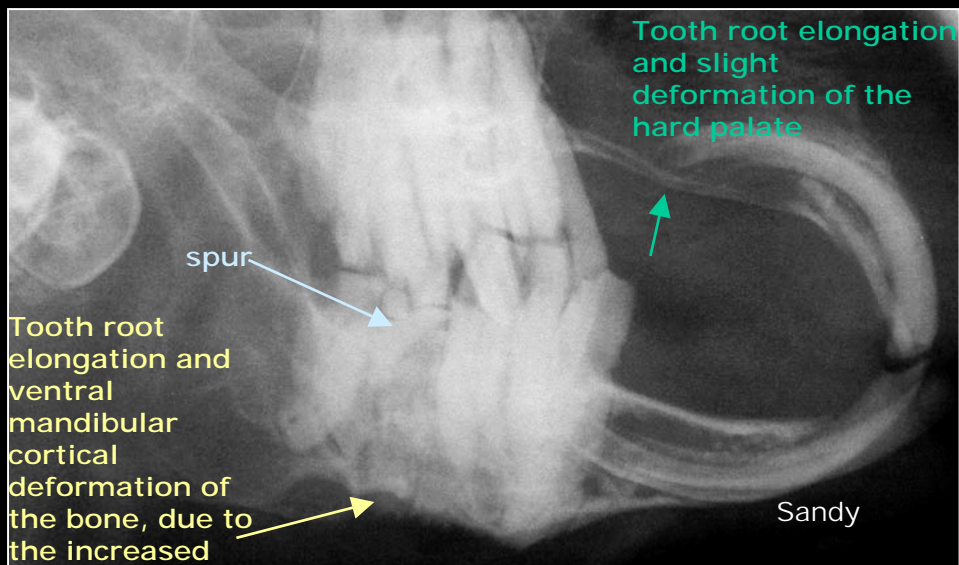




Radiograph of a rabbit suffering from severe malocclusion, before and after occlusal adjustment of the cheek teeth



Daniel

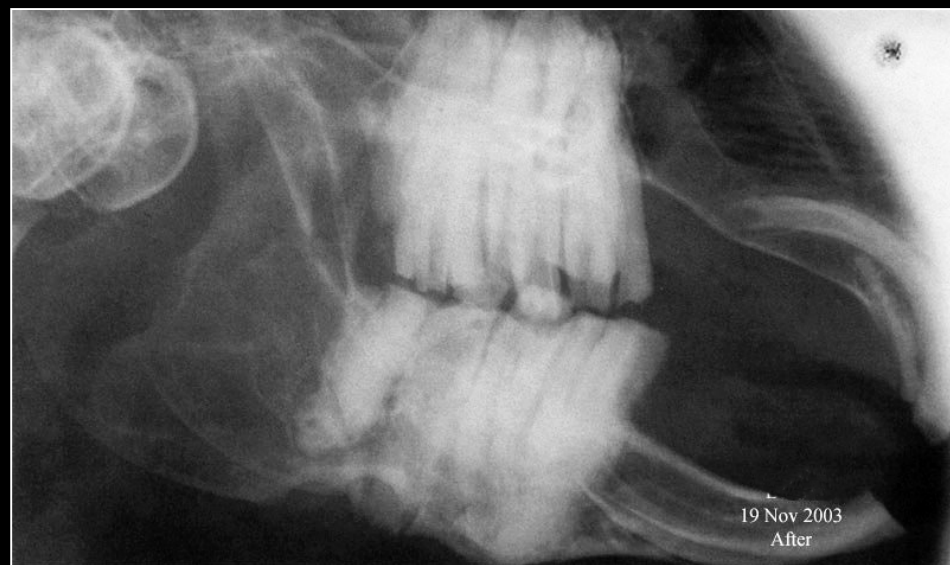

Sandy

Tooth root elongation and ventral mandibular cortical deformation of the bone, due to the increased pressure

Tooth root elongation and slight deformation of the hard palate

Before: severe malocclusion of cheek teeth, accompanied by tooth root elongation



19 Nov 2003
After

After: in order to adjust occlusion of the cheek teeth, premolars and molars have been filed, while incisors have been shortened.