

## *Female reproductive tract and ovariectomy (spay surgery)*

*Esther van Praag, Ph.D.*

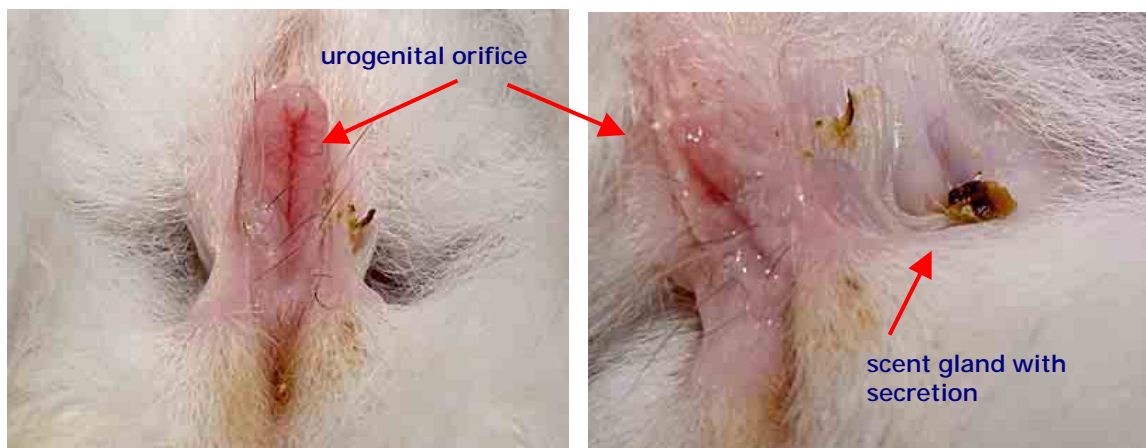Warning: this file contains pictures of the surgical procedure that may be distressing for people.

The reproductive organ of the female rabbit is considered primitive. Indeed, the split two-horned system is only encountered in monotreme egg laying mammals and the lagomorphs (pika, hare and rabbit). The organ is held in place by a broad ligament that is anchored at 4 points under the vertebral column.

Sex differentiation occurs during the embryonic phase, on the 16th day post-fertilization. The ovaries grow from an aggregate of cells that is lying near the original testes. The development of the ovaries is accompanied by the degeneration of the testes.

The development of the ovules (female reproductive cell) starts around the 21<sup>st</sup> day and continues till birth, around the 30<sup>th</sup> day. The first ova and follicles start to develop only 13 days after birth.

The reproductive organ of the female rabbit is duplex: the uterus is formed by two independent horns, split over their whole length ( $\pm 7$  cm). Each horn



VEIN (Veterinary Exotic Information Network) System, Copyright © Akira Yamanouchi

Left: View of the external female genital part  
Right: One of the scent glands, located on each side of the urogenital orifice, containing secretion



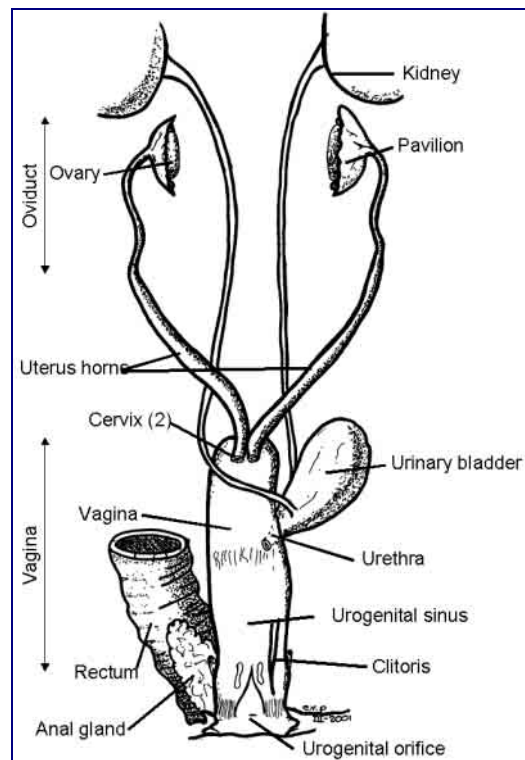
possesses its own cervix. The ovaries, ellipsoid bodies that have a maximal length of 1-1.5 cm, are located at the end of the uterus, right under the kidneys. They are hidden by the mesometrium (portion of the broad ligament that separates and encloses the uterus) and fat.

The vagina does not present any particularities. This part of the reproductive tract is large, with the urethra joining halfway, at the level of the vaginal vestibule. At the end of the vagina, the glands of Bartholin and preputial glands can be recognized.

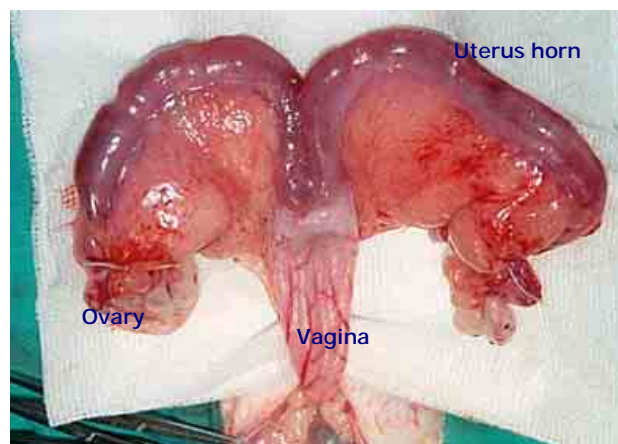
The age at which sexual maturity is reached depends on the size and the breed: while small and middle sized rabbits become adult between 4 and 6 months, it may take between 5 to 8 months for giant breeds. As a rule, it is considered that a rabbit is adult and able to reproduce when it has reached 75 to 80% of its adult size.

Female rabbits do not have an estrus (heat) cycle, as do other small animals like dogs or cats, but are called induced ovulators. Ovulation is spontaneous; it happens 9 to 13 h. after copulation.

A certain cycle does nevertheless exist. The presence of the estrogen



E. van Praag

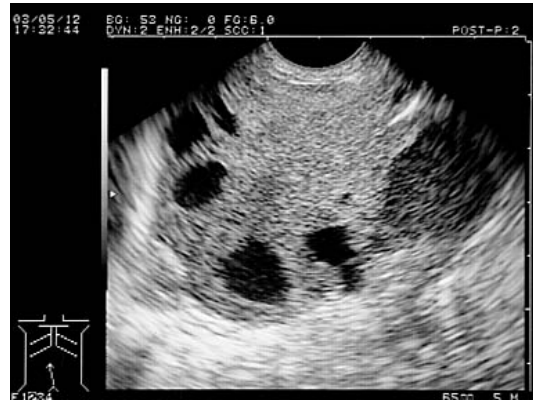
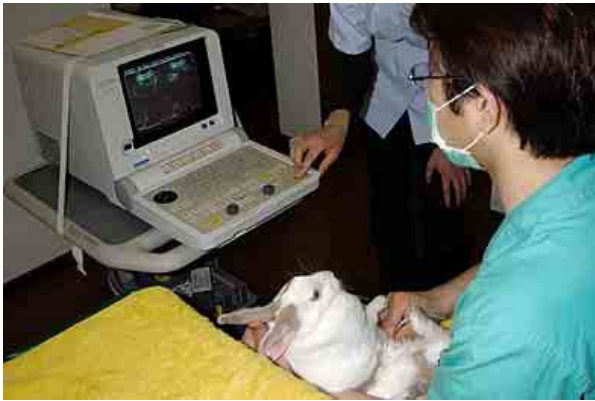

VEIN (Veterinary Exotic Information Network) System, Copyright © Akira Yamanouchi

Left: reproductive organs of the female rabbit

Right: View of ovaries, uterus and part of the vagina, during an ovariohysterectomy surgery





VEIN (Veterinary Exotic Information Network) System, Copyright © Akira Yamanouchi

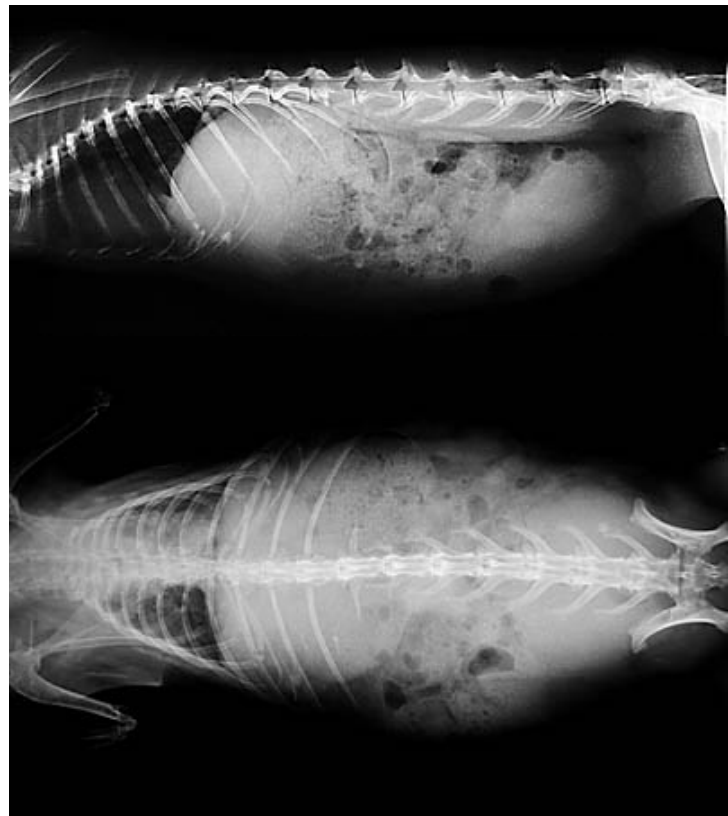Left: Taking an ultrasound of a rabbit  
Right: Presence of cancerous tumors determined by ultrasound

hormone will influence the size and the color of the vulva. Most female rabbits are more prone to mate when their vulva is colored reddish/purple. It is no clear indication though, as some female rabbits, called "reflex ovulators", will mate when their vulva is pale and small.

**Spay surgical procedure**

The spay of female rabbits is recommended in order to avoid unwanted litters, pseudo-pregnancies and reduce difficult behavior, like the marking of its territory with strong smelling urine, aggressive attitude and mounting of objects or human body parts like feet and arms. Further medical reasons to favor of a spay surgery include:

- difficult to treat bacterial infection or



VEIN (Veterinary Exotic Information Network) System, Copyright © Akira Yamanouchi

X-rays of a rabbit suffering from uterine adenocarcinoma



pyometra,

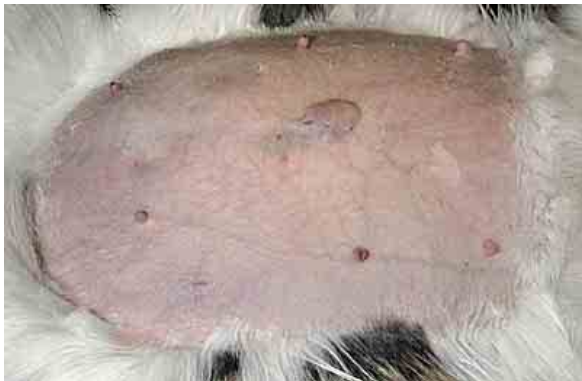- neoplasia of the ovaries or uterus (e.g. adenocarcinoma), a problem frequently seen in unspayed older rabbits,
- Abnormal swelling of the wall of the uterine artery (uterine aneurysm).

Ovariohysterectomy is a surgical procedure done under general anesthesia, in a sterile environment, with sterile surgical instruments and a preparation of the skin. Indeed, any post-surgical infection becomes a medical emergency.

An elective spay is usually done around the age of 5 months, or when the rabbit is sexually mature. At a younger age, the surgery is complicated by the difficulty to locate the very thin uterus and the very small ovaries. A spay at immature age may also have a dramatic effect on the proper calcium absorption by the bones.

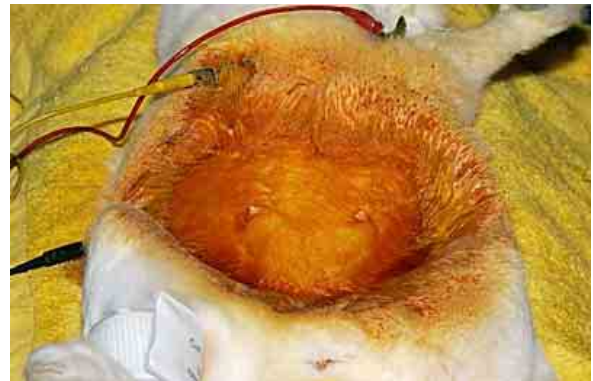If the spay is done in an older rabbit, it is advisable to do an ultrasound to determine whether there are tumors present, and, if found, to check for the presence of metastasis (e.g. in the lungs) before the surgery.

Various surgical approaches are available for ovariohysterectomy in rabbits, described in books, videos, or scientific articles.



1

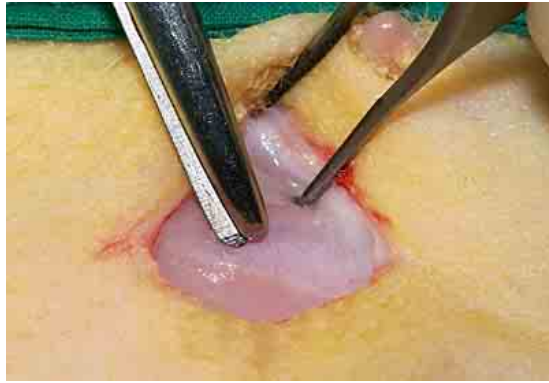The rabbit is anesthetized, and positioned in dorsal recumbency, with hind limbs restrained in extension. The fur is shaved.



2

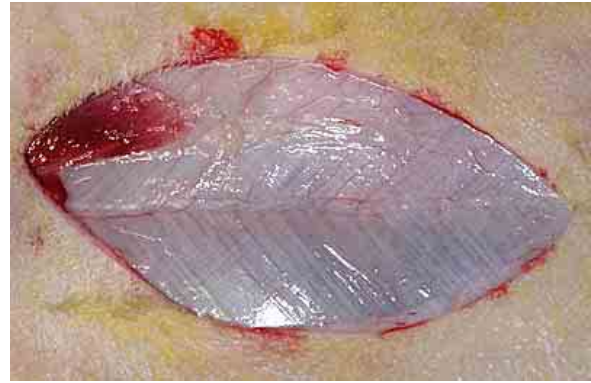The skin is scrubbed with a special surgical soap and an antiseptic solution. This step needs to be done carefully as rabbit skin is thin, friable and can easily be injured by tearing. The functions of the rabbit are monitored by means of a pulse oximeter and a respiratory monitor.





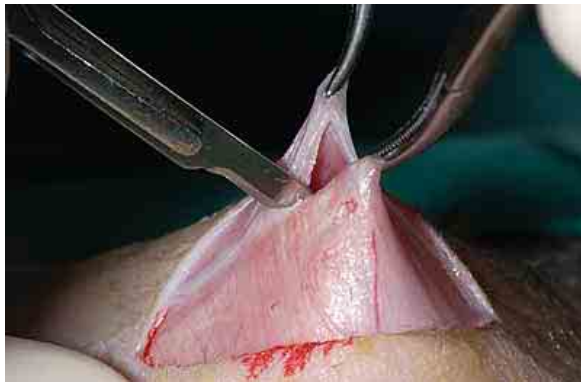3

A 1 to 3 cm midline incision is made through the skin, between the *ombilicus* and the cranial rim of the pelvis (or pelvis symphysis).



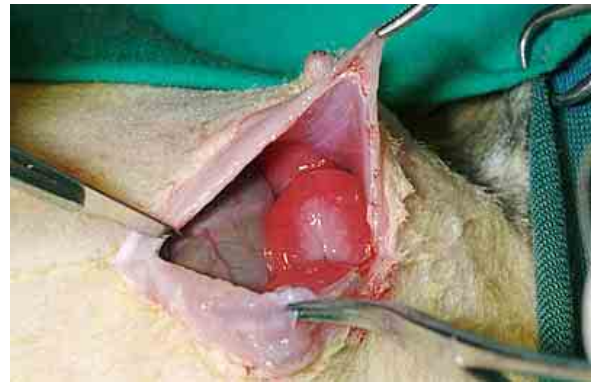
4

The skin is incised by means of scalpel or laser (longer procedure, but reduced bleeding) and the *linea alba* is located



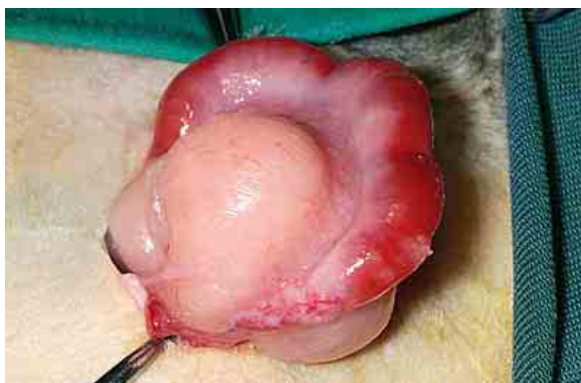
5

The body wall is elevated with forceps, to avoid damaging the underlying thin walls of the cecum and the bladder.



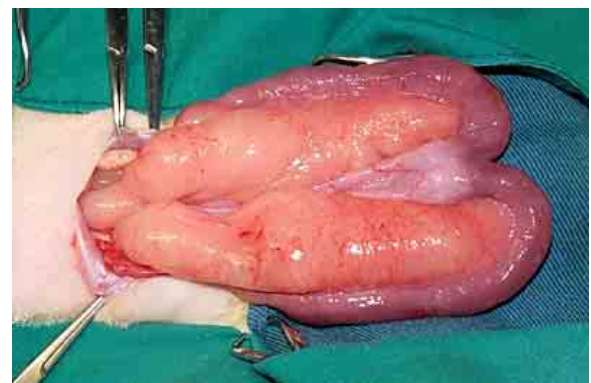
6

Closer look at the organ located under the incision. The uterus can be recognized by its pink color, while the intestine and cecum have a darker brown color.



7

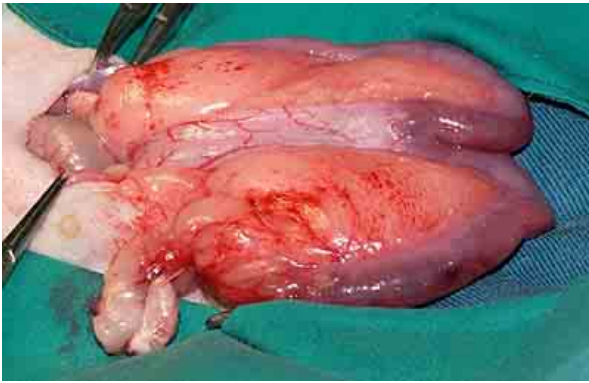
The uterus is located and exteriorized through the incision by gentle traction on the organ.



8

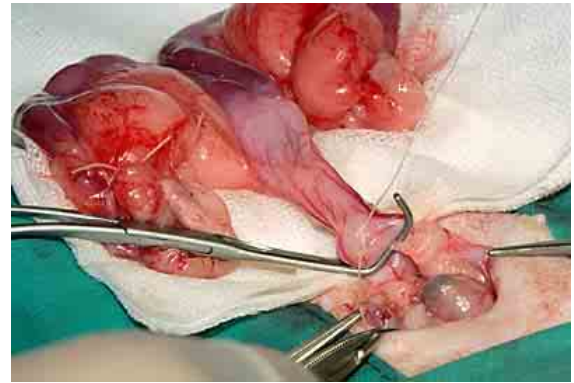
The exposition of the horns of the uterus, the cervix and the ovaries is possible, as the ovarian ligament is long.





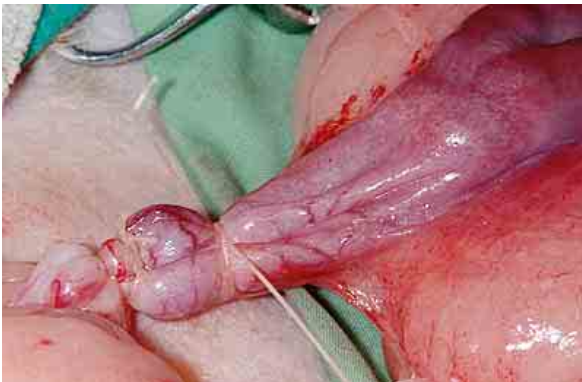9

The isolated opposite structures are carefully inspected. The presence of the ovaries is verified. Indeed, it happens that they are hidden among the fat deposits.



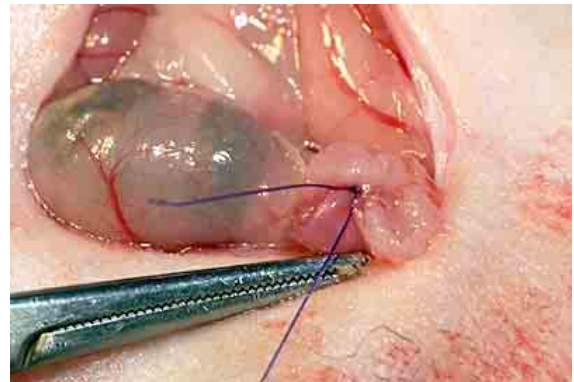
10

The body of the uterus below the horns is isolated and clamps are carefully placed. The fat tissue is removed and the ovarian pedicle isolated and ligated. The uterine artery and vessels supplying the broad ligament are also ligated. ATTENTION must be paid not to ligate the urethra and the caudal vesicular branch of the uterine artery, which supplies blood to the bladder.



11

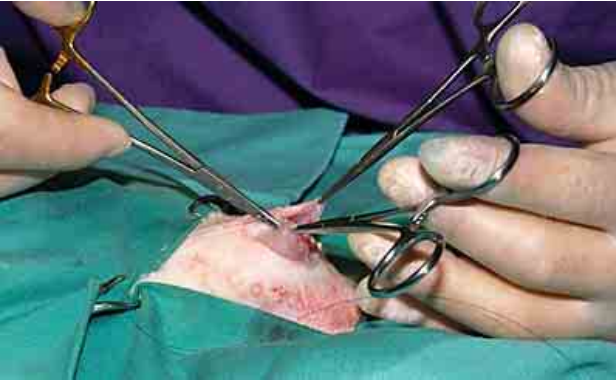The remaining tissue is carefully replaced through the incision.



12

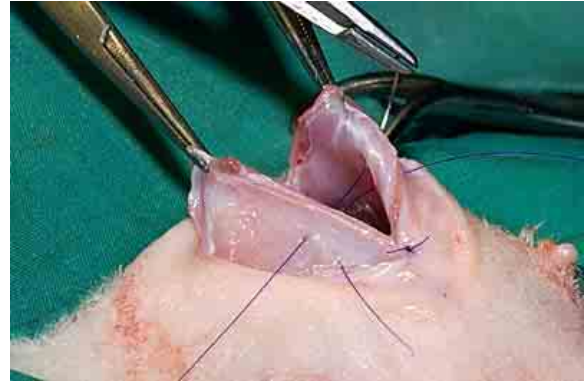
The remaining stumps are checked for hemorrhages, before placing them carefully back through the incision. A secure transfixated cervical ligature will prevent leakage of urine out of the vagina, into the abdominal cavity. It is also possible to ligate the vagina, so that no uterine tissue is left. This approach is more difficult though, due to the flaccid nature of the vaginal tissue. This approach may furthermore lead to the undesirable leakage of urine into the abdominal cavity, leading to possible bacterial infections.





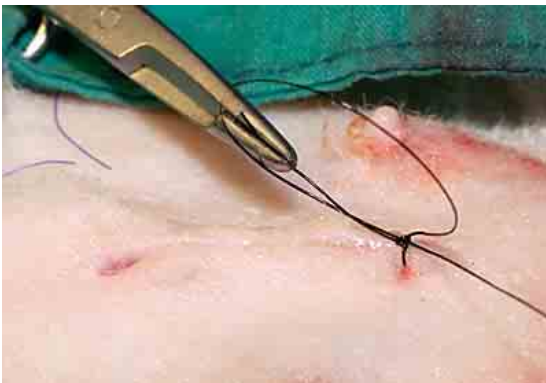13

The incision is closed by placing sutures. Some surgeons recommend suturing or gluing the subcutaneous tissues with acryl amide based products.



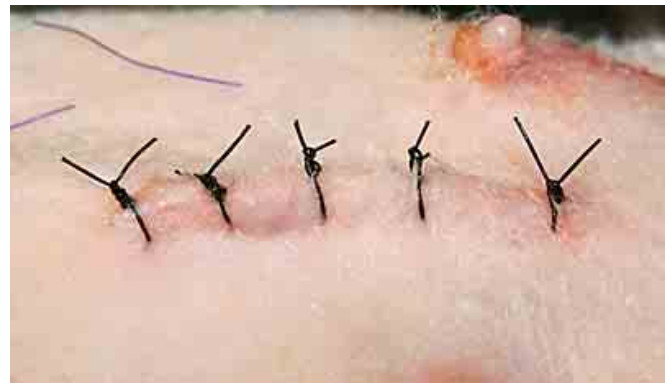14

The midlines are firmly sutured together again, layer after layer.



15

The incision is closed by placing several layers sutures in the subcutaneous layers and finally the skin. Since rabbits are notorious in breaking sutures, it is recommended to do several subcutaneous layers. Staples are thus a good alternative to sutures.



16

Finished !!!

### Post surgical care

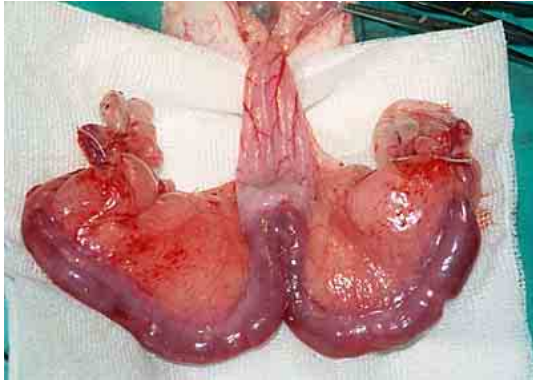
The administration of pain medication for several days after the surgery is highly recommended. Pain indeed induces hormonal, and physiological responses, which slow down the activity of the digestive tract, delay food intake and recovery.

The presence of blood in the urine during 24 to 48 hrs post-surgery is sometimes observed.

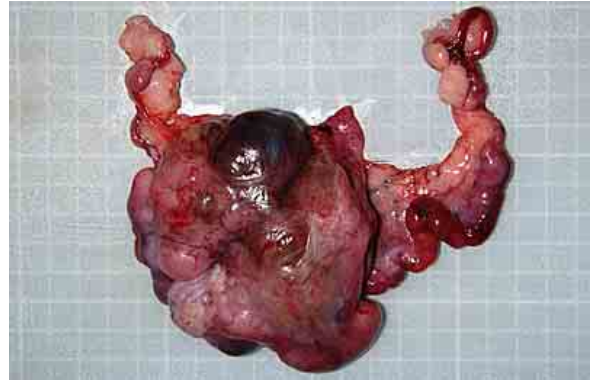
The rabbit should furthermore be confined for 7 to 10 days, and kept separated from other rabbits up to 10 days post-surgery.



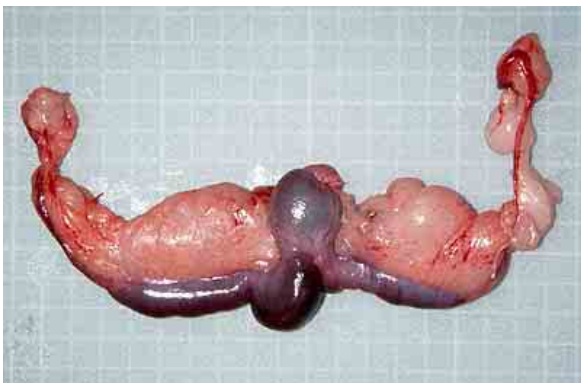
### Healthy and diseased female reproductive organs



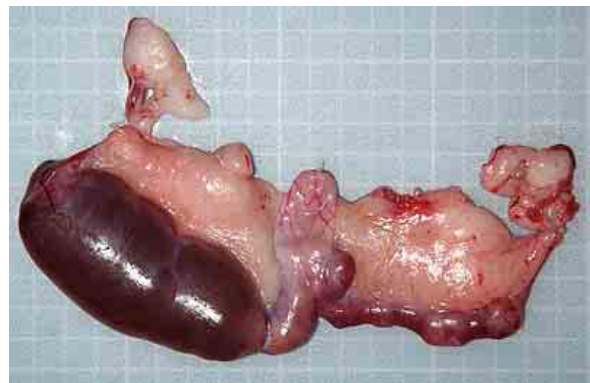
View of healthy ovaries and uterus.



Adenocarcinoma



Hematometra (accumulation of blood in the uterus)



Hydrometra (buildup of thin mucus or other watery fluid in the space of the uterus)

### Acknowledgement

All pictures used in these texts are from VEIN (Veterinary Exotic Information Network, <http://vein.ne.jp/>) and many thanks to Akira Yamanouchi, for giving me the permission to use them.

### Further Information

1. Atherton J, Griffiths L, Williams A. Cystic mastitis disease in the female rabbit. *Vet Rec.* 1999 Nov 27; 145(22):648.
2. Bray MV, Weir EC, Brownstein DG, Delano ML. Endometrial venous aneurysms in three New Zealand white rabbits. *Lab Anim Sci.* 1992 Aug; 42(4):360-2.
3. Cao T, Shirota T, Ohno K, Michi KI. Mineralized bone loss in partially edentulous trabeculae of ovariectomized rabbit mandibles. *J Periodontal Res.* 2004 Feb; 39(1):37-41.
4. Gilsanz V, Roe TF, Gibbens DT, Schulz EE, Carlson ME, Gonzalez O, Boechat MI. Effect of sex steroids on peak bone density of growing rabbits. *Am J Physiol.* 1988 Oct; 255(4 Pt 1):E416-21.



5. Hussein SA, Azab ME, Abdel-Maksoud H. Metabolic changes concerning the effect of castration on some blood constituents in male rabbits. Dtsch Tierarztl Wochenschr. 1999 Mar; 106(3): 113-8.
6. Jenkins JR. Surgical sterilization in small mammals. Spay and castration. Veterinary Clin North Am Exot Anim Pract. 2000 Sep; 3(3): 617-27, v. Review.
7. Lester-Cockx L. Neutering pet rabbits. Vet Rec. 1999 Mar 6; 144(10): 271.
8. Meredith A, Redrobe S, Keeble E. Neutering pet rabbits. Vet Rec. 1999 Mar 20; 144(12): 328.
9. Millis DL, Walshaw R. Elective castrations and ovariohysterectomies in pet rabbits. J. Am. Anim Hosp. Assoc. 1992: 491-497
10. Quesenberry KE, Carepenter JW, Quesenberry P. Ferrets, Rabbits and Rodents: Clinical Medicine and Surgery Includes Sugar Gliders and Hedgehogs, Elsevier Health, 2004.
11. Raftery A. Uterine adenocarcinoma in pet rabbits. Vet Rec. 1998 Jun 20; 142(25): 704.
12. Smith K. Rabbit Health in the 21st Century. A Guide for Bunny Parents, Second Edition <http://rabbithealth101.com/>
13. Harcourt-Brown F. Textbook of Rabbit Medicine, UK: Butterworth-Heinemann, 2001.
14. Flecknell P , editor. BSAVA Manual of Rabbit Medicine and Surgery, Gloucester, UK: British Small Animal Veterinary Association, 2000.
15. Sommerville LM. Treatment of a uterine adenocarcinoma in a domestic rabbit by ovariohysterectomy. Vet Rec. 1998 May 16; 142(20): 550-1.

---

*The information and pictures on these pages may not be reproduced, or republished on another webpage, website, or elsewhere.*

MAI 2004

