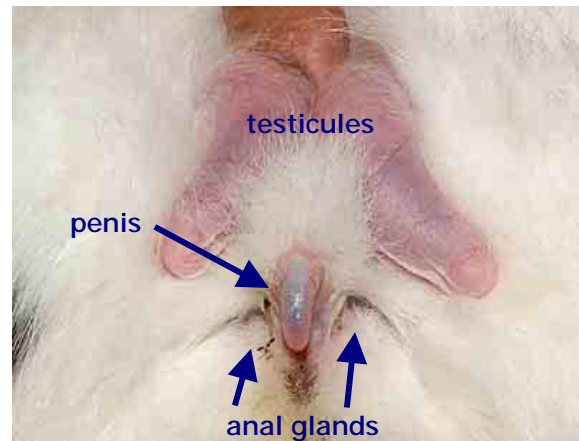
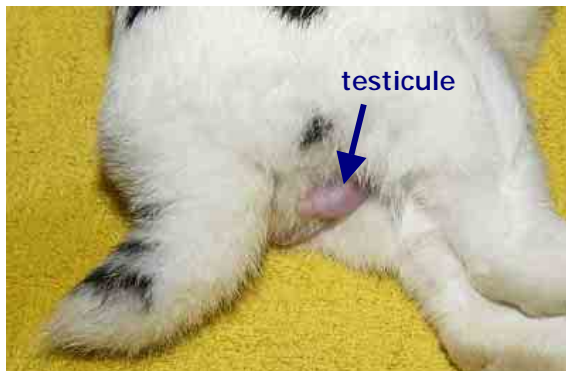

Male reproductive tract and orchidectomy (castration surgery)

Esther van Praag, Ph.D.

Warning: this file contains pictures of the surgical procedure that may be distressing for people.

The reproductive organs of the male rabbit are very similar to that of other mammals, except for the additional ability to retract the testis in the abdomen. They are formed during the embryonic phase. They derive from primitive ancestors of the kidney tubules and the ducts, except for the lobules of the testes and the *vasa recta*. The blood vessels of the kidney will



VEIN (Veterinary Exotic Information Network) System, Copyright © 2002 Shinkichi Tsuruno and Akira Yamanouchi

Left: Genital area of the male rabbit; scrotum and testicule in a mature male rabbit
Right: Genital area details: penis, testes and adjacent anal glands

furthermore be used and deviated in order to supply the testes and the scrotal wall with blood.

The reproductive organ of the male rabbit is composed of different structures. One of them are the testes, which is composed of various components:

- scrotal sacs: they are located in the inguinal area, ventrally to the anus and can be compared to a sac surrounded by skin and composed of muscles or connective tissue. They contain the testes

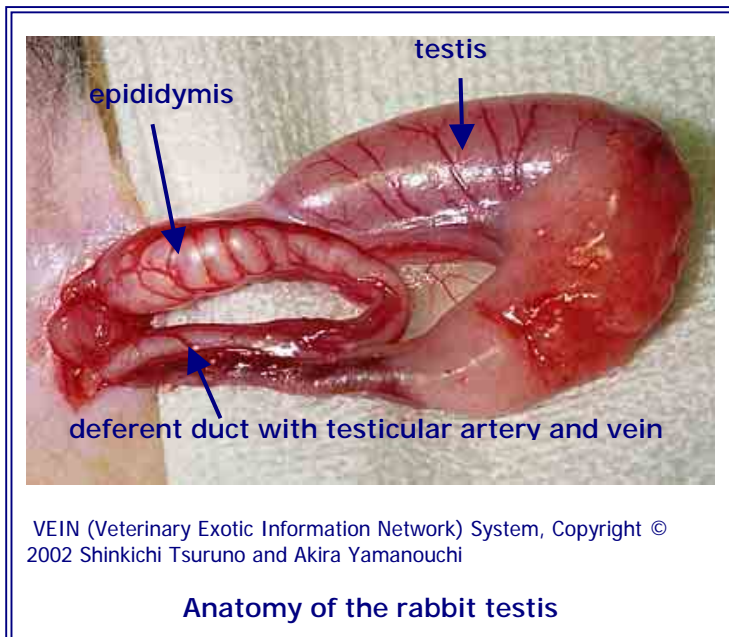


- testes: they are the reproductive gland, which is composed of tubular loops, lobules and a central tubular plexus (*vasa recta*).

The tubular lobules are lined with cells that develop the sperm, through a process of cell divisions (meiosis) and maturation. The sperm is brought to the tubular plexus (*vasa recta*). The later structure is furthermore lined with endocrine cells, secreting testosterone.

- epididymis: this is a coiled tube located at the surface of the testes.

The testes descent into the scrotum at the age of 2,5-3 months, and castration surgery is usually done at the age of 4 or 5 months. Male rabbits



possess a life-long ability to move freely their testis between the scrotum and the abdomen, via the inguinal ring. The response occurs during handling and examination, or during a fight between 2 males. Indeed, "entire" male rabbits will inevitably fight and attempt to "castrate" the other male by biting in the scrotal region.

Castration surgical procedure

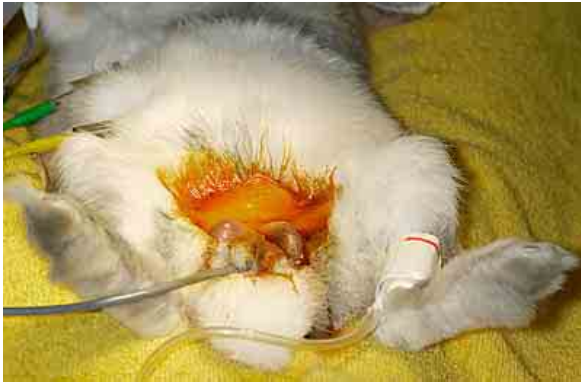The castration of male rabbits is recommended in order to reduce difficult behavior, like the marking of its territory with strong smelling urine, aggressive attitude and mounting of objects or human body parts like feet and arms. Further medical reasons to favor the castration surgery include:

- chronic difficult to treat orchitis or epididymitis
- neoplasia of the testes, though this is rare in rabbits.

Orchidectomy is done under general anaesthesia. It is a surgical procedure that requires sterile surgical instruments and a preparation of the skin, in order to minimize infection.

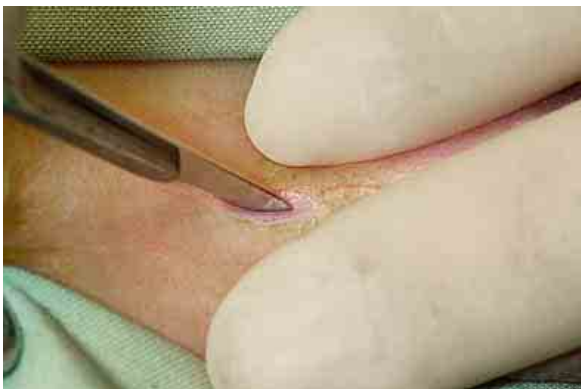Various surgical approaches are available for orchidectomy in rabbits, described in books, videos, or scientific articles. The following pictorial orchidectomy has been done according to the rather simple exterior extraction of the testis technique.





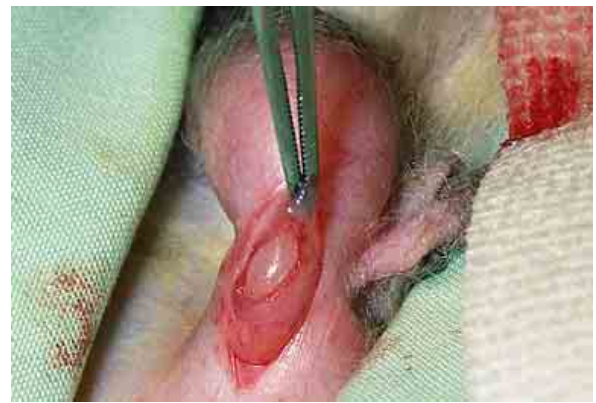1

Once the rabbit is anesthetized, and positioned in dorsal recumbence, the fur around the scrotum sacs is shaved and the skin is scrubbed with a special surgical soap and an antiseptic solution. This step needs to be done carefully as rabbit skin is thin, friable and can easily be injured by tearing. The rabbit is monitored by pulse oximetry and a respiratory monitor.



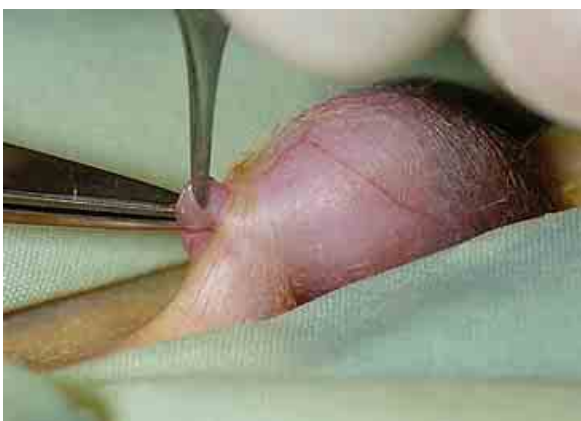2

A 1 cm incision is made through the skin, at the cranial end of the scrotum. The skin incised by means of scalpel or laser (longer procedure, but reduced bleeding).



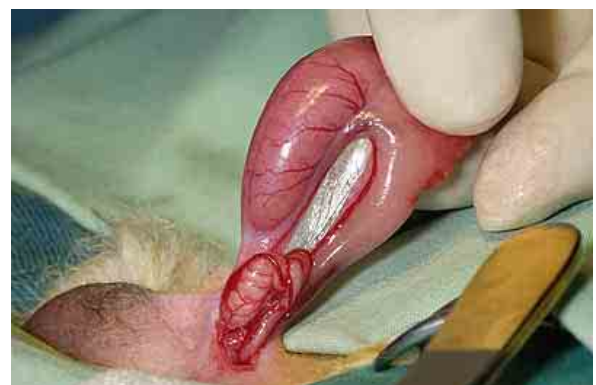3

The fibrous tunic is incised in order to isolate the testis and the connecting vessels. The vaginal tunic is exposed.



4

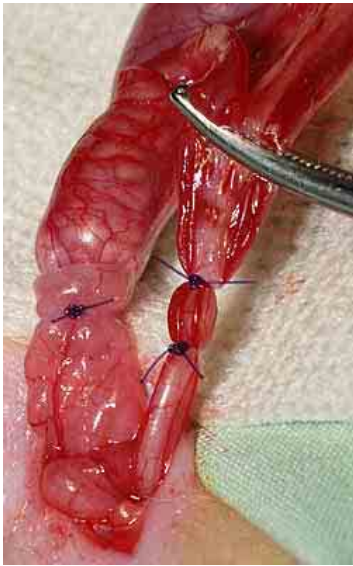
The tunic is localized and the testis is exteriorized.



5

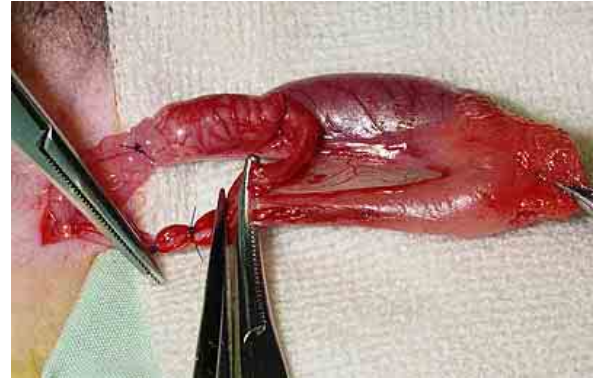
The testis, epididymis and the deferent duct are pushed and advanced through the incision.





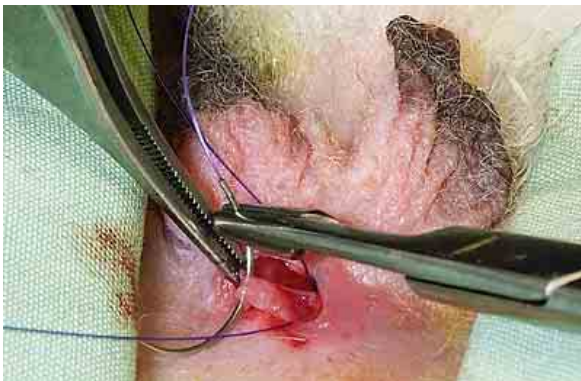6

The deferent duct and the blood vessels are clamped and sutured. An additional suture is needed around the entire structure, in order to close the inguinal ring and prevent herniation of the abdominal content, unless a closed castration technique is used.



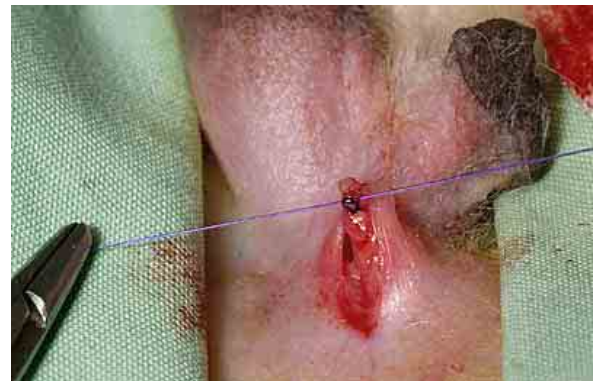7

The isolated structures are carefully inspected, before removal of the testis by cutting through the well-sutured spermatic cord. The later is important in order to avoid post-surgical scrotal hemorrhages. The final step is cutting of the ligament of the epididymis and the testis. No bleeding should happen at this stage of the surgery.



8


The remaining tissue is carefully replaced within the incision. Some surgeon's recommend suturing or gluing the scrotum with acryl amide based products.



9

The incision is closed by placing sutures in the subcutaneous tissues and in the skin level. Since rabbit are notorious in breaking suture, it is recommended to do several subcutaneous layers.





Post-surgical care

The administration of pain medication for at least 24 h. after the surgery is highly recommended. Pain indeed induces hormonal, and physiological responses, which slow down the activity of the digestive tract, delay food intake and recovery.

The presence of blood in the urine during 24 to 48 h post-surgery is normal. Sometimes, the scrotum is filled with blood and hemorrhaged. In rare cases, blood is observed to leak through the sutures. Bleeders, small blood vessels that cannot be ligated, cause this bleeding. It is a non-dangerous nuisance that can last a few days. The administration of vitamin K can help accelerate clotting, if the bleeding is still present after a few days.

The rabbit should furthermore be confined for 7 to 10 days, and kept separated from non-spayed females at least 4 to 6 weeks post-surgery.

Acknowledgement

All pictures used in these texts are from VEIN (Veterinary Exotic Information Network, <http://vein.ne.jp/>) and many thanks to Akira Yamanouchi, for giving me the permission to use them.

Further Information

1. Gilsanz V, Roe TF, Gibbens DT, Schulz EE, Carlson ME, Gonzalez O, Boechat MI. Effect of sex steroids on peak bone density of growing rabbits. *Am J Physiol.* 1988; 255(4 Pt 1):E416-21.
2. Hussein SA, Azab ME, Abdel-Maksoud H. Metabolic changes concerning the effect of castration on some blood constituents in male rabbits. *Dtsch Tierarztl Wochenschr.* 1999; 106(3):113-8.
3. Jenkins JR. Surgical sterilization in small mammals. Spay and castration. *Veterinary Clin North Am Exot Anim Pract.* 2000; 3(3):617-27, v. Review.
4. Millis DL, Walshaw R. Elective castrations and ovariohysterectomies in pet rabbits. *J. Am. Anim Hosp. Assoc.* 1992: 491-497



5. Quesenberry KE, Carepenter JW, Quesenberry P. Ferrets, Rabbits and Rodents: Clinical Medicine and Surgery Includes Sugar Gliders and Hedgehogs, Elsevier Health, 2004.
6. Smith K. Rabbit Health in the 21st Century. A Guide for Bunny Parents, Second Edition <http://rabbithealth101.com/>
7. Harcourt-Brown F. Textbook of Rabbit Medicine, UK: Butterworth-Heinemann, 2001, 192 page
8. Flecknell P , editor. BSAVA Manual of Rabbit Medicine and Surgery, Gloucester, UK: British Small Animal Veterinary Association, 2000,

The information and pictures on these pages may not be reproduced, or republished on another webpage, website, or elsewhere.

MAI 2004

