

SHORT PAPER

## Herpes Simplex Encephalitis in a Domestic Rabbit (*Oryctolagus cuniculus*)

P. Grest, P. Albicker\*, L. Hoelzle\*, P. Wild† and A. Pospischil

*Institute of Veterinary Pathology, \*Institute of Veterinary Bacteriology, and †Institute of Veterinary Anatomy, University of Zürich, 8057 Zürich, Switzerland*

### Summary

An adult domestic rabbit showing neurological signs was subjected to euthanasia. At necropsy, macroscopical lesions were absent. Histopathologically, extensive lesions were seen, particularly in the cerebral cortex. Non-suppurative meningitis was present and there was lymphocytic and plasmacytic perivascular cuffing in the neuropil. The cerebral cortex showed extensive segmental neuronal and glial necrosis. Within the necrotic areas, large amphophilic intranuclear inclusion bodies were present in neurons and glial cells. Immunohistochemically, neurons and glial cells in the affected areas were labelled by polyclonal antibodies against both herpes simplex virus-1 (HSV-1) and HSV-2. The agent was classified as HSV-1 by polymerase chain reaction analysis. This is only the second reported natural case of herpes simplex infection in a rabbit.

© 2002 Elsevier Science Ltd. All rights reserved.

Natural herpesvirus infections are rarely reported in rabbits. *Herpesvirus cuniculi* causes subclinical disease in New Zealand White rabbits, with no macroscopical lesions; histologically, however, mononuclear infiltrates and intranuclear inclusion bodies are seen in the testis (interstitial cells), skin (endothelial cells) and cornea (epithelial cells) (Maré, 1974). *Herpesvirus sylvilagus* causes lymphocytic myocarditis and myositis, interstitial pneumonia and lymphoproliferative diseases in cottontail rabbits (Hesselton *et al.*, 1988). A third, as yet unclassified, herpesvirus has been identified as the cause of a lethal disease in rabbits, characterized by haemorrhagic dermatitis, pneumonia, and necrotizing splenitis (Onderka *et al.*, 1992). The rabbit is an important animal model for herpesvirus disease of other species, e.g. malignant catarrhal fever (Buxton *et al.*, 1984), Aujeszky's disease (Jakubik, 1977) and bovine herpesvirus type 5 infection (Chowdhury *et al.*, 1997). In addition, the rabbit is an important model for human herpes simplex encephalitis (Schlitt *et al.*, 1986). This paper reports an isolated case of a naturally occurring herpes simplex encephalitis in a domestic rabbit in Switzerland. To our knowledge, there has been only one other case worldwide (Weissenböck *et al.*, 1997).

A 1-year-old male dwarf rabbit, kept as a house pet without companion, was brought to the clinic with mild pruritus and restlessness. One week later the rabbit exhibited neurological symptoms (e.g. sudden running and tonic-clonic spasms) every 3 to 4 h. Later, the animal became laterally recumbent and was humanely destroyed. At necropsy, no macroscopical lesions were evident. Histologically, however, severe lesions were observed in the cerebral cortex, with prominent involvement of the temporal and parietal lobes. The meninges were mildly to moderately affected, and within the mesencephalon and rhombencephalon only minimal lesions were present. The spinal cord was not examined. A mild meningitis (Fig. 1) was present and mild to moderate perivascular cuffing was seen in the neuropil, composed of lymphocytes, plasma cells and histiocytes. Multiple sharply demarcated areas consisting of acute neuronal and glial necrosis, accompanied by a minimal inflammatory reaction, were evident in the cerebral cortex (Fig. 2). Many neurons and glial cells within these areas contained intranuclear, baso- to amphophilic inclusion bodies, often filling the entire nucleus (Fig. 3). In addition, a bilateral focal malacia with reactive invasion of gitter cells was present in

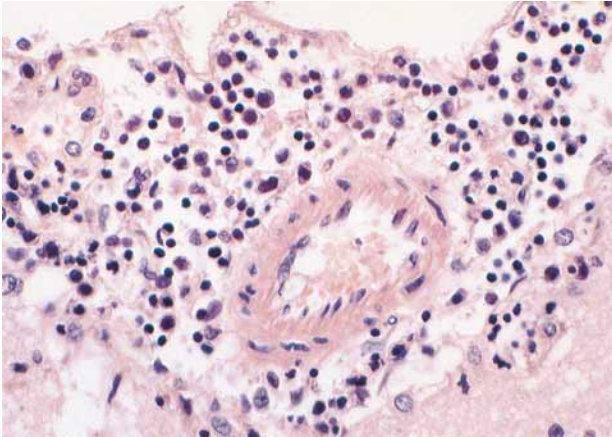


Fig. 1. Meninges: moderate, diffuse, non-purulent inflammatory infiltrate. Haematoxylin and eosin (HE).  $\times 227$ .

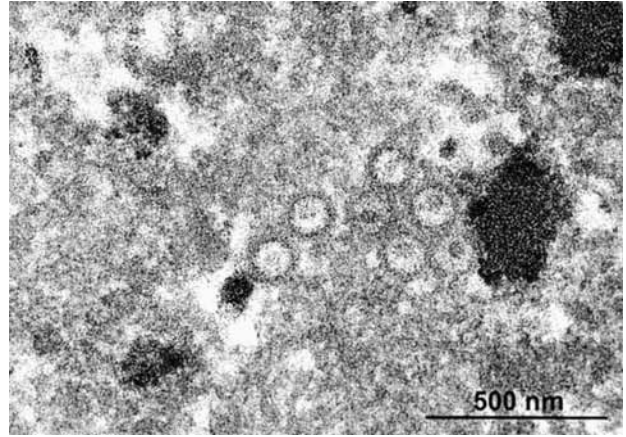


Fig. 4. Intranuclear nucleocapsids (approximately 100 nm in diameter). EM.

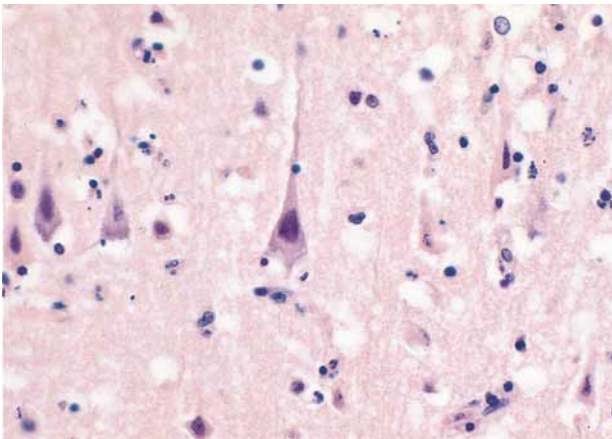


Fig. 2. Cerebral cortex: acute neuronal and glial necrosis. HE.  $\times 227$ .

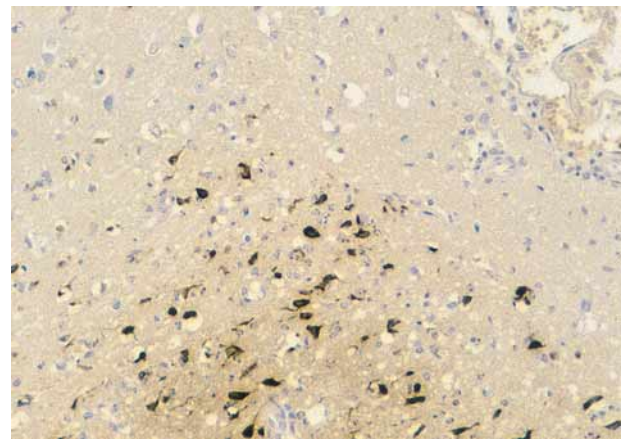


Fig. 5. Cerebral cortex: neurons and glial cells positively immunolabelled for HSV-1. Peroxidase-antiperoxidase technique.  $\times 114$ .

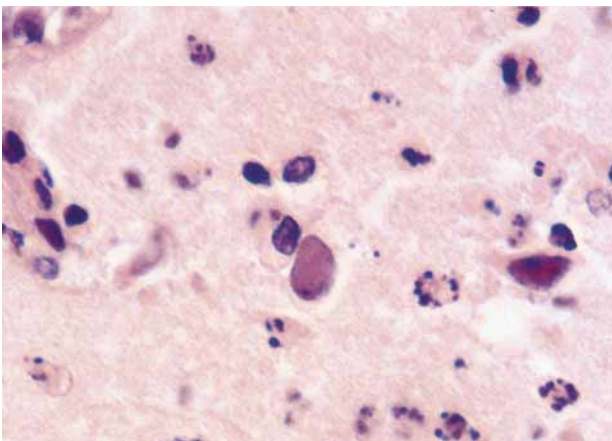


Fig. 3. Cerebral cortex: intranuclear inclusion bodies in neurons. HE.  $\times 570$ .

the frontal lobe. No inclusion bodies were detected in this area.

Paraffin wax-embedded material was processed for electron microscopy (EM), which revealed intranuclear particles with the typical morphology of herpesvirus (Fig. 4). In addition, immunohistochemical examination was performed with polyclonal antibodies against herpes simplex virus type 1 (HSV-1) and 2 (Dako®, Zug, Switzerland). The peroxidase-antiperoxidase method with diaminobenzidine as chromogen was applied. Neurons and glial cells within the necrotic area were positively labelled with both antisera, showing a homogeneous brown staining of the cytoplasm and in some cases of the nucleus (Fig. 5). For the polymerase chain reaction (PCR), genomic DNA

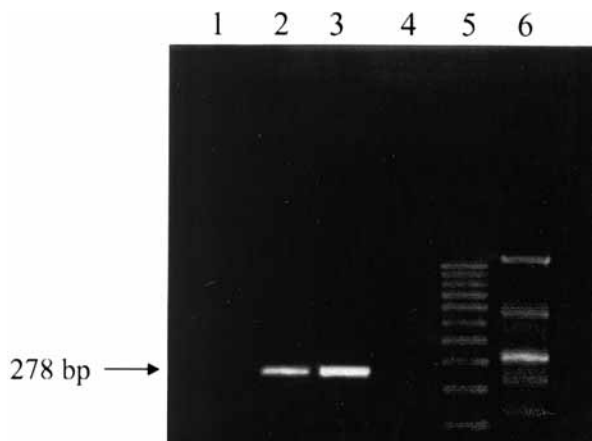


Fig. 6. Polymerase chain reaction. Lane 1, negative control (brain, rabbit); lane 2, DNA extract from the infected rabbit; lane 3, positive control (cosmid-DNA containing UL42-gene of HSV-1); lane 4, negative control ( $H_2O$ ); lane 5, 100 bp ladder; lane 6, genomic DNA of bovine herpes virus (BHV-1, specificity control).

was extracted from paraffin wax-embedded brain tissue. Thereafter, a HSV-1 UL42-gene-specific PCR was performed as previously described (Puchhammer-Stöckl *et al.*, 1990). Paraffin wax-embedded brain tissue of a rabbit without lesions was used as a negative control. Cosmid-DNA containing the UL42 gene of HSV-1, which was kindly provided by Prof. Ackermann, Institute of Veterinary Virology, Zürich, served as a positive control. In addition, genomic bovine herpes virus (BHV-1) DNA was used as a specificity control for the primer pair used. Molecular sizes of the amplification products relative to those of the 100-bp DNA ladder were assessed by a computer-aided bio-image system (BioProfil 3·1, LTF, Wasserburg, Germany). PCR results are shown in Fig. 6.

In the case described, the histological lesions were consistent with those seen after experimental infection with herpes simplex (Schlitt *et al.*, 1986) and with the lesions observed by Weissenböck *et al.* (1997) in an earlier case of naturally occurring herpes simplex encephalitis in a rabbit. In experimental infections, the distribution pattern varies according to the route of infection. Corneal inoculation (Paivarinta *et al.*, 1994) enables the virus to enter via the trigeminal system, resulting in lesions in the brain stem and cerebral hemispheres, affecting particularly the ventral parts of the limbic system. Intraocular inoculation (Narang and Codd, 1978) is followed by lesions restricted to the nervus opticus, the chiasma opticum and the corpus geniculatum. Direct inoculation into the bulbus olfactorius (Schlitt *et al.*, 1986) and viral spread via

the nervus olfactorius leads to focal lesions in the lobus temporalis and lobus frontalis. Similar lesions have been observed after intranasal inoculation with herpes simplex and subsequent reactivation of latent infections (Stroop and Schaefer, 1986). In the present case no lesions were evident in the brain stem or in the corpus geniculatum, and this would argue against trigeminal entry. The lesions were restricted to cortical areas of the lobus temporalis, lobus frontalis and lobus parietalis, suggesting infection through the bulbus olfactorius. The nasal mucosa would seem to offer a route for viral entry, since the ends of the olfactory cells, which are bipolar neurons, and their basal processes continue to the brain as axons of the nervus olfactorius.

A person with a herpetic infection was known to have had close contact with the rabbit described in this report, and may have provided the source of infection. Because it has been shown experimentally that rabbit to rabbit transmission sometimes occurs (Kaplan, 1969), there seems no reason why contact infection of rabbits from human beings should not also occur. As mentioned above, however, we are aware of only one other reported natural case of herpes simplex encephalitis in a rabbit. The absence of further cases is surprising, as rabbits are easily infected with herpes viruses experimentally, and large numbers of pet and laboratory rabbits live in close contact with human beings and would therefore seem to be at risk. Possibly, few rabbits with unexplained nervous symptoms are made available for histological examination, which is an essential step in diagnosis. Alternatively, horizontal transmission may, for unknown reasons, be a rare event.

## References

- Buxton, D., Reid, H. W., Finlayson, J. and Pow, I. (1984). Pathogenesis of 'sheep-associated' malignant catarrhal fever in rabbits. *Research in Veterinary Science*, **36**, 205–211.
- Chowdhury, S. I., Lee, B. J., Mosier, D., Sur, J. H., Osorio, F. A., Kennedy, G. and Weiss, M. L. (1997). Neuropathology of bovine herpesvirus type 5 (BHV-5) meningo-encephalitis in a rabbit seizure model. *Journal of Comparative Pathology*, **117**, 295–310.
- Hesselton, R. M., Yang, W. C., Medveczky, P. and Sullivan, J. L. (1988). Pathogenesis of *Herpesvirus sylvilagus* infection in cottontail rabbits. *American Journal of Pathology*, **133**, 639–647.
- Jakubik, J. (1977). Comparative susceptibility of rabbits, rats, mice and pigs to infection with Aujeszky diseases virus (ADV) in the development of an efficacy test for ADV vaccines. *Zentralblatt für Veterinärmedizin, B*, **24**, 764–766.

- Kaplan, A. S. (1969). Herpes simplex and pseudorabies virus. *Monographs in Virology*, **5**, 61–66.
- Maré, C. J. (1974). Viral diseases. In: *The Biology of the Laboratory Rabbit*, S. H. Weisbroth, R. E. Flatt and A. L. Kraus, Eds, Academic Press, New York, pp. 237–257.
- Narang, H. K. and Codd, A. A. (1978). Progression of herpes encephalitis in rabbits following the intra-ocular injection of type I virus. *Neuropathology and Applied Neurobiology*, **4**, 457–470.
- Onderka, D. K., Papp-Vid, G. and Perry, A. W. (1992). Fatal herpesvirus infection in commercial rabbits. *Canadian Veterinary Journal*, **33**, 539–543.
- Paivarinta, M. A., Roytta, M., Hukkanen, V., Marttila, R. J. and Rinne, U. K. (1994). Nervous system inflammatory lesions and viral nucleic acids in rabbits with herpes simplex virus encephalitis-induced rotational behaviour. *Acta Neuropathologica (Berl)*, **87**, 259–268.
- Puchhammer-Stöckl, E., Popow-Kraupp, T., Heinz, F. X., Mandl, C. W. and Kunz, C. (1990). Establishment of PCR for the early diagnosis of herpes simplex encephalitis. *Journal of Medical Virology*, **32**, 77–82.
- Schlitt, M., Lakeman, A. D., Wilson, E. R., To, A., Acoff, R. W., Harsh, G. R. 3rd and Whitley, R. J. (1986). A rabbit model of focal herpes simplex encephalitis. *Journal of Infectious Diseases*, **153**, 732–735.
- Stroop, W. G. and Schaefer, D. C. (1986). Production of encephalitis restricted to the temporal lobes by experimental reactivation of herpes simplex virus. *Journal of Infectious Diseases*, **153**, 721–731.
- Weissenböck, H., Hainfellner, J. A., Berger, J., Kasper, I. and Budka, H. (1997). Naturally occurring herpes simplex encephalitis in a domestic rabbit (*Oryctolagus cuniculus*). *Veterinary Pathology*, **34**, 44–47.

[ Received, June 19th, 2001 ]  
[ Accepted, January 7th, 2002 ]