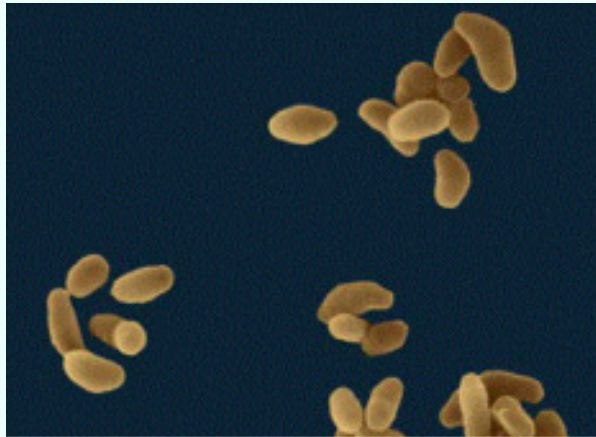


## ***Tularemia in rabbits***

*Esther van Praag, Ph.D.*

The bacterium *Francisella tularensis* leads to the development of acute blood poisoning in hares, rabbits as well as in other animals like birds and even human beings. Rabbits, hares and rodents are most sensitive to the bacterium and the disease is fatal for them. It is suspected that the later are responsible for the epidemic spread of the diseases in some regions. .



[www.zkea.com/archives/archive02009.html](http://www.zkea.com/archives/archive02009.html)

*Francisella tularensis*

The disease is mainly found on the American continent, in Russia and in Scandinavia. There are nevertheless regions in Western Europe where the bacterium is endemic (e.g. Alsace, France). The bacterium is spread by blood-sucking insects (lice, ticks, flies, mosquitoes) but can also be spread by skin contact, through respiration or by contaminated food.

*Francisella* sp., which has been classified with the bacterial family of *Brucella* sp. and *Pasteurella* sp., is a tiny (it can barely be seen with a regular light microscope), Gram negative, immobile and aerobic coccobacillus. The most virulent strains are mainly observed in the USA.

The disease is rarely seen in rabbits, and contamination from a domestic rabbit to a human being has not been described so far.

### Clinical signs

Although the time between infection and the death of the rabbit is rapid, the disease is usually discovered after the death of the animal only.

The first clinical signs are a decrease appetite, depression, ataxia (blocked ability to coordinate movements) and a certain inclination to remain together with other rabbits.



The visible symptoms are the presence of skin abscesses and infection of the lymphatic glands (nodular form of the disease). In severe cases, the disease can be accompanied by pneumonia and septicemia

An autopsy often shows the presence of bleedings in the pleura and an accumulation of blood in the lungs. The liver is enlarged and the presence of blood clots is observed in this organ as well as in the spleen. The lymph nodes are usually swollen.

### Diagnosis

This disease is very contagious to human beings, and extra safety measure must be taken during the treatment and the lab work.

*Francisella* sp. grows only on a special media, rich in blood like the blood cystine medium. A further analytical tool is the ELISA test.

### Treatment

As in human beings, streptomycin or other aminoglycoside antibiotics are given to the rabbit. The advantage of tetracycline antibiotics is that it can be administered orally, but often, the disease is recurrent after the treatment is halted.

### Further information

1. Frolich K, Wisser J, Schmuser H, Fehlberg U, Neubauer H, Grunow R, Nikolaou K, Priemer J, Thiede S, Streich WJ, Speck S. Epizootiologic and ecologic investigations of European brown hares (*Lepus europaeus*) in selected populations from Schleswig-Holstein, Germany. J Wildl Dis. 2003; 39:751-61.
2. Garcia del Blanco N, Gutierrez CB, de la Puente VA, Rodriguez Ferri EF. Biochemical characterization of *Francisella tularensis* strains isolated in Spain. Vet Rec. 2004; 154:55-6.
3. Lepitzki, D. A., A. Woolf, and M. Cooper. 1990. Serological prevalence of tularemia in cottontail rabbits of southern Illinois. J. Wildl. Dis. 26:279-282.
4. Morner T, Mattsson R, Forsman M, Johansson KE, Sandstrom G. Identification and classification of different isolates of *Francisella tularensis*. Zentralbl Veterinarmed B. 1993; 40:613-20.
5. Morner T. The ecology of tularaemia. Rev Sci Tech. 1992; 11:1123-30
6. Manning, P J, Ringer DH, Newcomer, CE, The Biology of the Laboratory Rabbit. (1994). Academic Press, New York, New York.

---

*The information and pictures on these pages may not be reproduced, or republished on another webpage, website, or elsewhere.*

SEPTEMBER 2005

