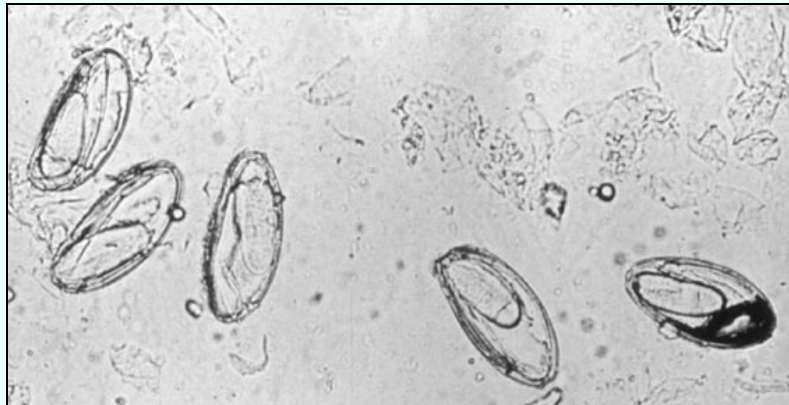


## *Passalurus ambiguus*

*Esther van Praag, Ph.D.*

This parasite is also known as *Oxyuris ambigua*. It is a common, cosmopolitan parasite that infests wild or house-rabbits cottontails and hares. *P. ambiguus* is specific to lagomorphs and does not have a public health significance. In the USA, the presence of *P. nonanulatus* has also sometimes been observed in rabbits. Auto-infection is common through ingestion of the eggs with the food. The juvenile stages of *Passalurus* spp. are rather found in the mucosa of the small intestine and the cecum, while the adult worms are located in the anterior part of the cecum and the large intestine of rabbits.

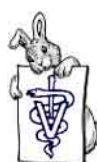The life cycle of *Passalurus* spp. is direct: the eggs are ingested by the animal. The eggs have typically a flat side and measure about 100\*43  $\mu\text{m}$ . During their development, the resistance to dehydration increases. The larvae will emerge from the eggs and develop in the mucous layer of the small intestine and the cecum, where they develop into mature adults. Two molts are reported, one at 24 h. and the other on the third day.



[www.parasitology.org/imagehtml/Taxei.htm](http://www.parasitology.org/imagehtml/Taxei.htm)

Eggs of *Passalurus ambiguus*

The adult worms have different sizes, the males being smaller ( $\pm 5$  mm) than the females ( $\pm 10$  mm). The females, characterized by a long and narrow tail, are marked with about 40 circular, cuticular striations. It seems that the female worms deposit the eggs around the anus. The worms live about 106 days in one rabbit.



### Clinical Signs

*Passalurus* spp. parasites are non-pathogenic and there are generally no clinical signs of its presence, even in cases of heavy infection. A rabbit may be infested with over 1000 parasitic worms. Eggs and occasionally live adult worms can be observed in the feces only, not around the anus. It is interesting to note that the female worms emerging from the anus of rabbits contain eggs in the gastrula stage, that are able to develop into an infective stage in the environment.

The presence of mucus in the droppings, frequently as threads, is an indicated of the presence of intestinal worms, but this condition should be differentiated from mucoid enteritis.

The presence of worms has been linked to cases of cecal impaction, accompanied by stasis, terrible pain and gas

At necropsy, *Passalurus* spp. worms have found in the lumen of the cecum, the crypts and mucosa of the colon. The site where the worms were located was inflammatory and presented dystrophic modifications. The most profound inflammatory and dystrophic changes were found in the cecum. Signs of vascular dystrophy were furthermore observed in the hepatic and renal parenchyma.



Simone van der Meij

Left and Middle: Rabbit droppings with hair (fine white thread) and worms  
Right: Dropping with live roundworm

### Diagnosis

The presence of intestinal parasites is determined by a fecal flotation test. In rare cases, the fecal flotation test result of heavily infested rabbit can return negative. When left untreated, the presence of worms can often be observed in the droppings.



Treatment:

<b>Piperazine</b>	piperazine adipate	200 mg/kg PO, repeated in 14 days (Hillyer and Quensenberry, 1997),
<b>Benzimidazoles</b>	fenbendazole	10-20 mg/kg, PO, repeat in 10-14 days
	thiabendazole	100-200 mg/kg PO, one treatment (Brown, 1993), 110 mg/kg one treatment + 70 mg/kg for eight doses (Hillyer and Quensenberry, 1997).
	mebendazole	20-50 mg/kg one treatment
	oxibendazole	15 mg/kg, repeated in 14 days
<b>Macrolides</b>	ivermectin	0.4 mg/kg, <b>is completely ineffective</b> (Tsui and Patton, 1991).

Acknowledgement

Thanks are due to thank Simone van der Meij, and her rabbit Jasper, for the pictures or worm infested droppings.

Further Information

1. H. Boecker (1953) Die Entwicklung des Kaninchen Oxyuren *Passalurus ambiguus*. Zeitschrift für Parasitenkunde 15: 491-518.
2. S. Brown (1993) Rabbit Drug Dosages. Rabbit Health News 10: 6-7
3. J. Burke (1994) Clinical Care and Medicine of Pet Rabbits. In: Proceedings of the Michigan Veterinary Conference, pp 49-77.
4. D. Duwel and K. Brech (1981) Control of Oxyuriasis in Rabbits by Fenbendazole. Lab. Anim. Sci. 15: 101-105.
5. A.B. Erickson (1944) Helminth Infection in Relation to Population Fluctuations in Snowshoe Hares. J. Wildl. Manage. 8: 134-153.
6. E.V. Hillyer, K.E. Quesenberry (1997) Ferrets, Rabbits, and Rodents. Clinical Medicine and Surgery. W.B. Saunders Company pp.
7. J.P. Hugot (1984) L'Insémination Traumatique chez les Oxyures de Dermoptères et de Léporidés. Etude Morphologique Comparée. Ann. de Parasitologie Humaine et Comparée 59: 379-385.
8. M.A. Palimpsestov, R.S. Chebotarev (1935) Zur Frage des Therapie bei Passalurose (*Passalarus ambiguus*) des Kaninchen. Tierärztliche Rundschau 41: 709-711.
9. N.M. Patton, K.W. Hagen, J.R. Gorham, R.E Flatt (1986) "Domestic Rabbits: Diseases and Parasites. "Pacific Northwest Extension Publ. Oregon, Idaho, and Washington.
10. K.I. Skrjabin, N.P. Shikhobalova, E.A. Lagodovskaya (1960) Oxyurata of Animals and Man. Part I. Oxyuroidea. In: Skrjabin, K.I. (ed.), Essentials of Nematology, The Academy of Sciences of the U.S.S.R., Moscow (published by the Israel Program for Scientist Translations, Jerusalem, 1974).



11. J. Theodoris (1979) Contribution to the study of parasites in the rabbits of Northern Greece. *hellinike Kteniatrike (Hellenii Veterinary Medecine)* 22: 181-183.
12. T.L.H Tsui and N.M. Patton (1991) Comparative Efficiency of Subcutaneous Injection Doses of Ivermectin against *Passalurus ambiguus* in rabbits *J. Appl. Rabbit Res.* 14: 266-269.
13. N.B. Walden (1999) Rabbits: a Compendium (The T.G. Hungerford VADE MECUM series for Domestic Animals: Series C.13). Post Graduate Foundation in Veterinary Science, University of Sydney, Sydney.
14. J.P. Wiggins, M. Cosgrove, H. Rothenbacher (1980) Gastrointestinal Parasites of Eastern Cottontail Rabbits (*Sylvilagus floridanus*) in Central Pennssylvania. *J. Wildl. Dis.* 16:541-544.
15. Fujiwara H, Uchida K, Takahashi M. [Occurrence of granulomatous appendicitis in rabbits] *Jikken Dobutsu.* 1987; 36(3):277-80.
16. Shirokova EP, Grishina EA. [Microstructural changes in the organs of the rabbit with passaluriasis] *Med Parazitol (Mosk)* 1997; (2):18-21

---

*The information and pictures contained in these pages cannot be reproduced, or republished on another webpage, website, or elsewhere.*

JUNE 2003  
updated: January 2007

