

Meibomian cyst or the development of a white nodule on the rabbit eyelid

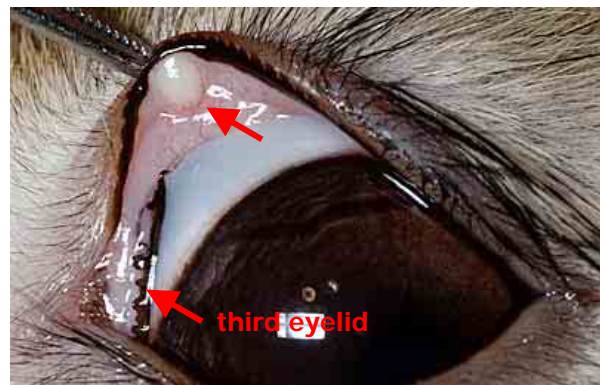
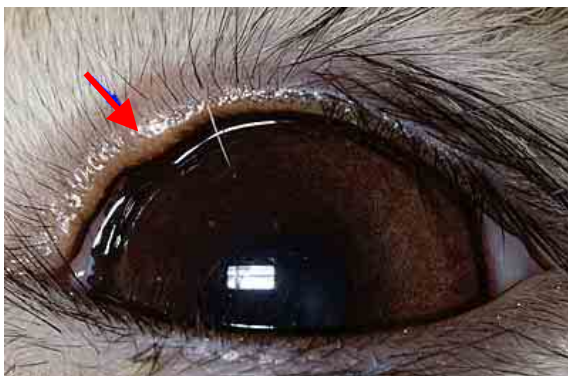
Esther van Praag, Ph.D.

Caution: this file contains pictures that may be distressing for some persons.

The meibomian glands, located in the tarsal plate of the eyelid, are sebaceous (oil-secreting) glands whose secretions help lubricate the eyelids. Sometimes the glands become impacted or blocked. A meibomian cyst, also called chalazion will develop. It is a slowly growing, painless firm nodule, usually located on the upper or lower eyelid. The accumulation of secretions within the glands is caused either by an impaction of the gland opening, a thickening of the oil or the presence of a tumour next to the glands that hinder proper drainage by compressing the opening. The distended gland may rupture and the freed material will irritate the surrounding tissue, which becomes granulomatous. The accumulation of secretion on the edge of the lids can lead to the development of bacteria normally found on the skin, or of pathogen bacteria like *Staphylococcus* sp. or *Streptococcus* sp. If the nodule is infected, it becomes painful and swollen.

Diagnosis

Although the clinical signs are evident, the meibomian cyst must be differentiated from conjunctivitis, from a hordeolum (sty, a localized



VEIN (Veterinary Exotic Information Network) System, Copyright © Akira Yamanouchi

**Left: Swelling, or meibomian cyst, as seen on the outside of the eyelid of a rabbit.
Right: Meibomian cyst, as seen when the eyelid is lifted and the inside is seen.**

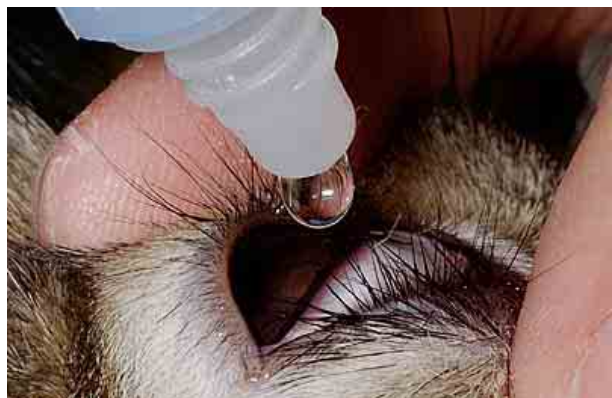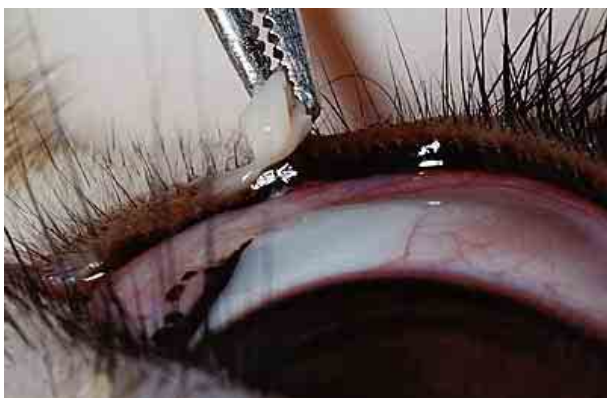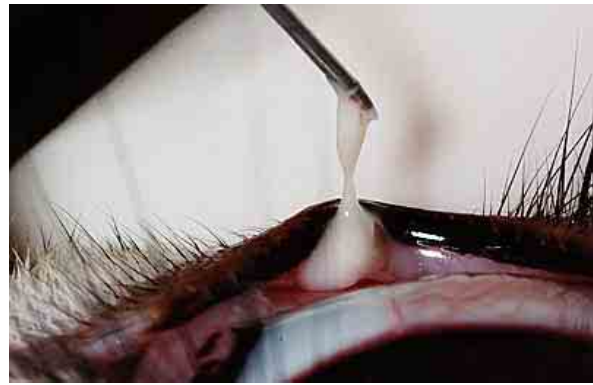
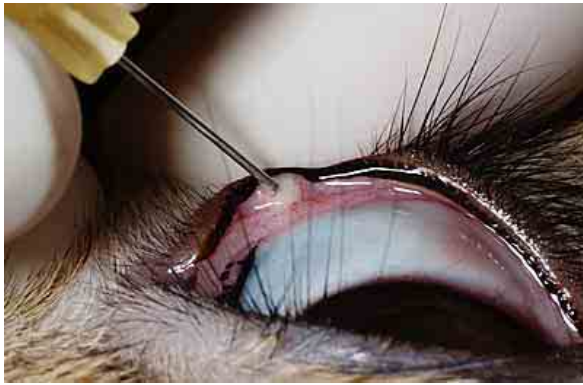


infection or inflammation of the eyelid margin involving hair follicles of the eyelashes). Blepharitis, meibomianitis, or meibomian cell carcinoma are further problems that should not be overlooked.

Treatment

Sometimes, a meibomian cyst will disappear by itself, without need of treatment. The swelling can be brought down by the application of warm compresses on the eye, 4 to 5 times a day. If a bacterial infection is present, administration of antibiotics is necessary.

Usually, the cyst is lanced with a needle or a small incision, and the oozing gelatinous pus is removed. Curettage of the cavity follows. This step is repeated till the cavity is devoid of remaining material. The loose material is removed by flushing the cavity with a saline solution. If bleeding appears, the application of pressure on the wound with a sterile gauze pad during a few minutes will stop it. The process of coagulation takes a few minutes. An antibiotic ointment is given immediately after the procedure.



VEIN (Veterinary Exotic Information Network) System, Copyright © Akira Yamanouchi

**Upper Left: Lancing of the cyst (chalazion) with a needle,
Upper right: Removal of the thick gelatinous pus,
Lower left: Vigorous curettage will eliminate any remaining material,
Lower right: Administration of an antibiotic ointment in the eye, after the surgical procedure.**



Due to injection of anesthetic agents in the eyelid, the use of clamping tools and forceps, the eyelid usually looks bruised and swollen after the procedure. This is normal and should disappear over the next days.

If the cyst is large, persistent or infected, surgical excision of the inflammatory granuloma is advisable. If the removed cyst presents tumor-like characteristics, it should be sent for analysis to a pathological laboratory.

Post-surgical care includes the use of an antibiotic ointment during a few days and the gentle application of cold compresses, in order to reduce the swelling.

Usually, no pain medication is necessary. When the rabbit shows signs of pain or discomfort, meloxicam or ibuprofen can be given.

Acknowledgement

Thanks are due to Akira Yamanouchi, for the permission to use the pictures from VEIN (Veterinary Exotic Information Network, <http://vein.ne.jp/>).

Further information

1. Greiner JV, Glonek T, Korb DR, Whalen AC, Hebert E, Hearn SL, Esway JE, Leahy CD. Volume of the human and rabbit meibomian gland system. Adv Exp Med Biol. 1998; 438:339-43.
2. Millar TJ, Pearson ML. The effects of dietary and pharmacological manipulation on lipid production in the meibomian and harderian glands of the rabbit. Adv Exp Med Biol. 2002; 506(Pt A):431-40.
3. Steagall RJ, Yamagami H, Wickham LA, Sullivan DA. Androgen control of gene expression in the rabbit meibomian gland. Adv Exp Med Biol. 2002; 506(Pt A):465-76.
4. Tiffany JM, Marsden RG. The meibomian lipids of the rabbit. II. Detailed composition of the principal esters. Exp Eye Res. 1982; 34:601-8.
5. Tiffany JM. The meibomian lipids of the rabbit. I. Overall composition. Exp Eye Res. 1979 ;29:195-202.

The information and pictures on these pages may not be reproduced, or republished on another webpage, website, or elsewhere.

AUGUST 2005

