

Fibrosarcoma in rabbits

Esther van Praag, Ph.D.

Caution: this file contains pictures that may be distressing for some persons.

The word "sarcoma" comes from the Greek and means "fleshy growth". Sarcoma is nowadays used to describe relatively rare a group of malignant tumors that involve the connective tissue. Although sarcomas are well-recognized tumors, their characteristics lead to confusion. Indeed, some type of sarcoma may present a combination of features of various different



J. Hymel

Sparky suffering from recurrent fibrosarcoma

types of sarcoma. This lead to the widely accepted conclusion that the neoplastic development of a primitive mesenchymal cell can lead into different direction, thus different types of sarcoma.

The tumors are found is all parts of the body: forelimbs, hindlimbs, chest, and abdomen; as well as in all types of tissues:

muscle tissue, nerves, tendons, scar tissue, bones and their lining.

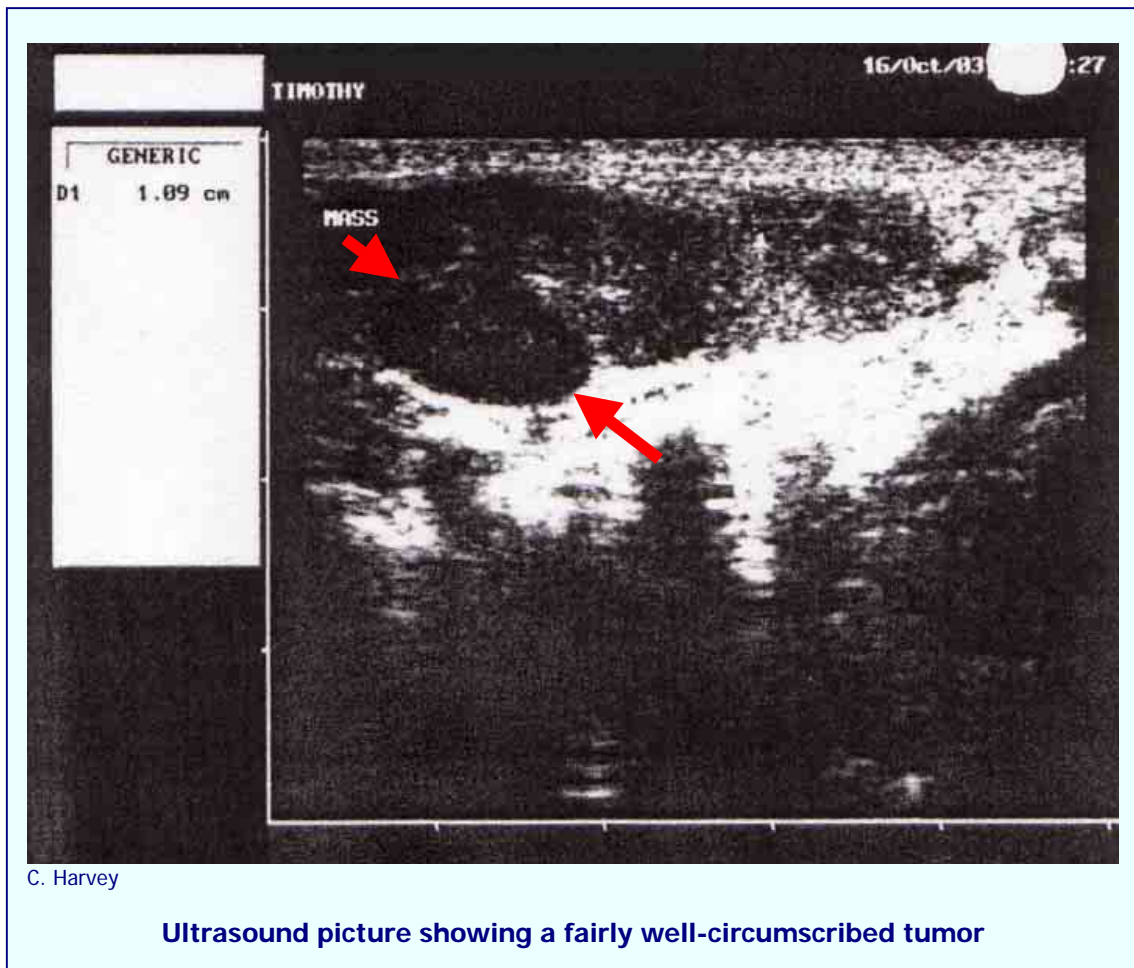
Four principles apply for sarcoma tumors:

- **location:** a superficially located tumor is less likely to be malignant than a deeper located tumor.
- **size:** bigger tumors are more likely to become malignant than small tumors.
- **growth:** rapid growth tumors are more likely to be malignant than slow growing ones.



- **Vascularization:** malignant tumors are rich in blood vessels, whereas benign tumors are avascular or poorly vascularized.

Sarcoma tumors are locally invasive into the surrounding tissues. Although their metastatic rate is low, they can metastasize through the bloodstream to other organs.



Fibrosarcoma seems more frequent in rabbits as generally assumed. These mesenchymal tumors are aggressive, have generally a rapid growth rate and are invasive into surrounding tissues, e.g. muscle or periosteum (tissue lining bones). Indirect invasion or transport of a metastatic cell via the bloodstream is possible and metastasis can form in the lungs, heart, kidneys and lymph nodes.

A virus called "malignant rabbit fibroma virus" has been isolated in rabbits and can lead to fibrosarcoma. It presents antigenic similarities with the fibroma and myxoma viruses, it is thought to be a recombinant of both viruses, but this is not yet well defined. The presence of this virus is accompanied by immunodepression, malignant tumors and infections.



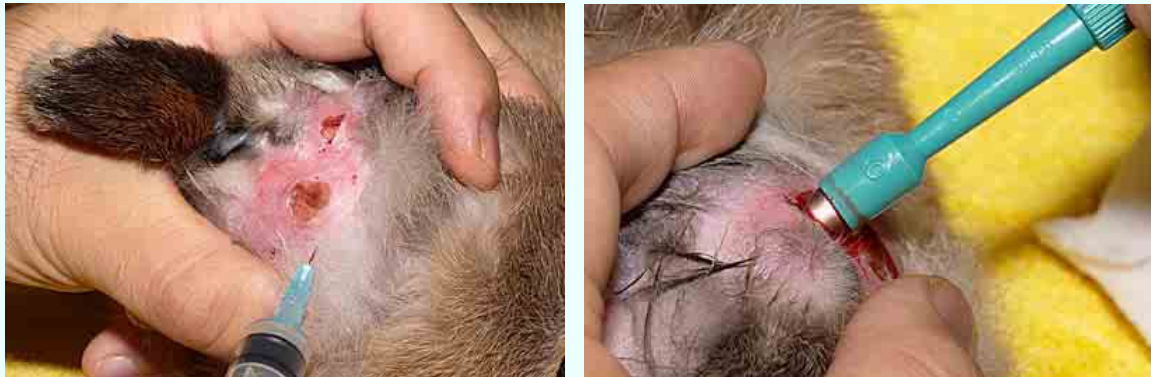In rare cases, the fibrosarcoma can present myxoid features and will develop into a myxosarcoma.

See: "[Myxoid sarcoma or myxosarcoma in rabbits](#)"

Diagnosis and Histology

The nature of the mass and the presence of metastases must be determined. This can be done by X-ray, ultrasound, and a biopsy.

Fibrosarcoma are heterogenous. The presence of "fishbone-shaped" fusiform cells within a collagenic stroma is characteristic and characteristic for a neoplasm of mesenchymal origin. Numerous cells are undergoing mitosis. Necrotic or hemorrhagic foci are commonly observed.



VEIN (Veterinary Exotic Information Network) System, Copyright © 2001-2002 Shinkichi TSURUNO and Akira Yamanouchi

Left: Injection of an anesthetic agent in the skin
Right: Punch biopsy sampling for histopathological examination

Treatment

The complete excision of the fibrosarcoma lesions is necessary. If a limb is affected, amputation is the option of choice. Chemical treatments have been administered to rabbits suffering from fibrosarcoma, in order to reduce the size of the tumor in rabbits.

Treatment 1:

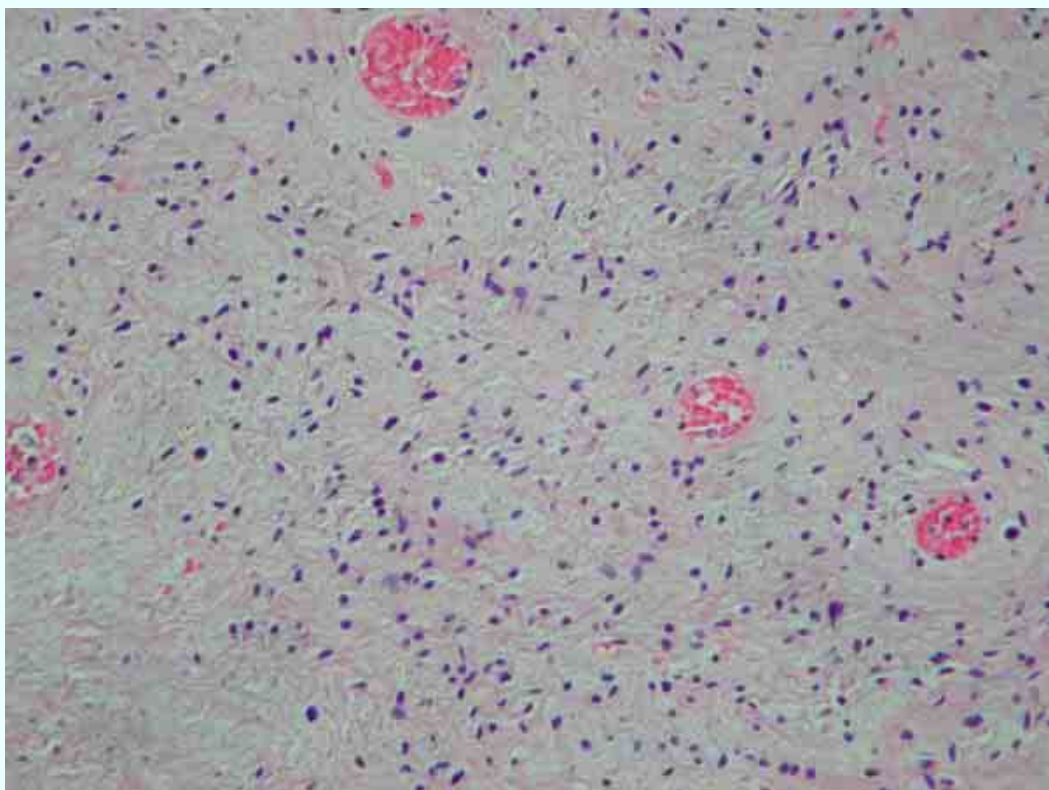
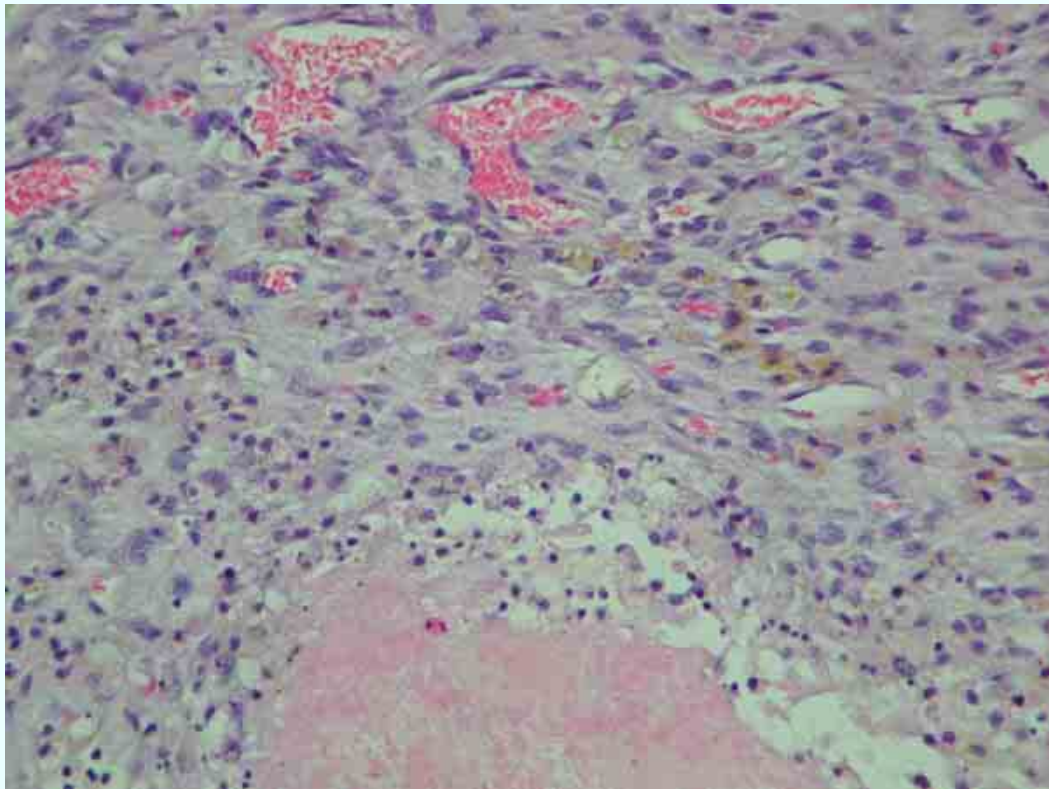
- 1 mg/kg adriamycin IV q. 3 weeks, through peripheral catheter,
- cytoxan: standard cat dose 4 days/week, PO
- L-asparaginase (Elspar): standard cat dose,
- 2mg/kg prednisone daily.

Treatment 2:

- prednisone and L-asparaginase (Elspar) alone.

A characteristic of fibrosarcoma tumors is their high rate of recurrence (according to species, up 70% within year of surgical removal).



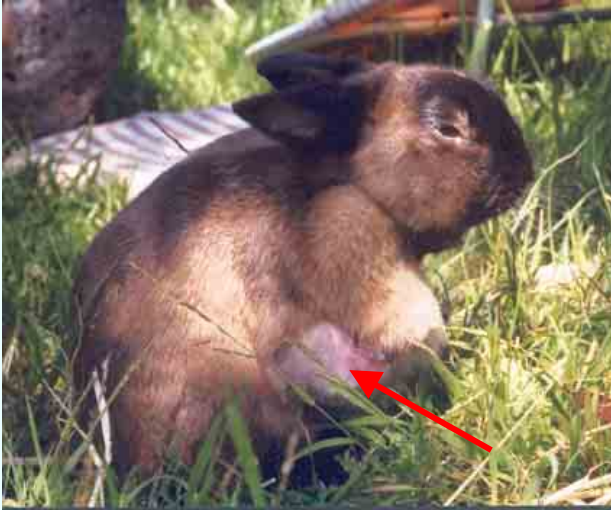

E van Praag

Top: Microscopic view of the fibrosarcoma tumor, removed from Sparky
Bottom: Microscopic view of spindle cells and blood vessels with erythrocytes



At recurrence, these lesions gain a higher grade of aggressiveness and an increased potential to become malignant. The prognosis is therefore guarded.



Juliet Brown



Left: Atticus before surgery: fibrosarcoma attached to the forelimb
Right: after surgery: amputation in order to remove completely the tumor.

Acknowledgements

Thanks are due to C. Harvey, DVM (USA), Susan L. (USA), Jeff Hymel (USA), and Akira Yamanouchi ((Veterinary Exotic Information Network, <http://vein.ne.jp/>, Japan), for providing the illustrative material for this text. Thanks are also due to Sparky and Atticus, for his patience during picture-sessions.

Further information

1. Flecknell P., editor Gloucester, BSAVA Manual of Rabbit Medicine and Surgery, UK: British Small Animal Veterinary Association 2000.
2. Hillyer E.V. and Quesenberry K.E., Ferrets, Rabbits, and Rodents: Clinical Medicine and Surgery, New York: WB Saunders Co. 1997.
3. Janssens G, Simoens P, Muylle S, Lauwers H. Bilateral prolapse of the deep gland of the third eyelid in a rabbit: diagnosis and treatment. Lab Anim Sci. 1999; 49(1):105-9.
4. Manning P.J., Ringler D.H., Newcomer C.E., The Biology of the Laboratory Rabbit, New York: Academic Press 1994.
5. Renfrew H, Rest JR, Holden AR. Extraskelatal fibroblastic osteosarcoma in a rabbit (*Oryctolagus cuniculus*). J Small Anim Pract. 2001; 42(9):456-8.

The information and pictures on these pages may not be reproduced, or republished on another webpage, website, or elsewhere.

FEBRUARY 2004

updated: mai 2005

